

EVALUATION OF TRANSCRESTAL HYDRODYNAMIC PIEZOELECTRIC INTERNAL SINUS ELEVATION WITH SIMULTANEOUS IMPLANT PLACEMENT. (A CLINICAL AND RADIOGRAPHIC STUDY)

Nada M. Fahmy¹*MSc, Nevein SH. Abdulla² PhD, Samraa Elsheikh² PhD,
Adham ElAshwah³ PhD.

ABSTRACT

INTRODUCTION: Hydrodynamic piezoelectric surgery is a sophisticated approach to internal sinus elevation that uses a transcrestal technique to reduce postoperative complications such as sinus floor perforation, bleeding, and implant malfunction.

AIM OF THE STUDY: The goal of this study stood to assess how the minimally invasive hydrodynamic piezoelectric internal sinus elevation procedure performed with or without bone grafting and simultaneous implant insertion and the affected clinical outcomes.

MATERIALS AND METHODS: A sum of 30 maxillary sinuses were chosen to meet a set of inclusion and exclusion criteria (patients with missing molars or premolars). A computer mechanism randomly separated the participants into three groups. At all surgical sites, cone beam CT (CBCT) was used to assess the residual bone height present between the crest of the alveolar bone and the floor of the sinus, as well as the bone breadth needed for the proper implant size and placement. All groups had an elevated transcrestal mucoperiosteal flap. Both study groups A and B had sinus lifting surgeries with and without bone grafts, as well as simultaneous implant installation with a hydrodynamic piezoelectric lift. A sinus floor elevation surgery was performed on the control group C, and implant implantation at the same time. In each group, the bone height obtained following sinus augmentation was measured using (CBCT).

RESULTS: Piezoelectric sinus lift revealed good significant difference $p < 0.05^*$ in the bone height gained after the Schneiderian membrane elevation with minimal postoperative complications concerning pain, edema and membrane perforation compared to the conventional osteotomes. The conflicts between the two study groups and the other control group were confirmed to be statistically significant.

KEYWORDS: Maxillary sinus elevation, Piezoelectric surgery, Intralift, Conventional instruments technique, Transrectal sinus floor elevation.

RUNNING TITLE: Effect of Piezoelectric surgery on internal sinus elevation

1. Assistant Lecturer of Oral and Maxillofacial Surgery, Department of Oral and Maxillofacial Surgery, Faculty of Dentistry, Arab Academy for Science Technology & Maritime Transport (AASTMT), Egypt

2. Professor of Oral and Maxillofacial Surgery, Department of Oral and Maxillofacial Surgery, Faculty of Dentistry, Alexandria University, Egypt.

3. Assistant Professor of Oral and Maxillofacial Surgery, Department of Oral and Maxillofacial Surgery, Faculty of Dentistry, Alexandria University, Egypt

* Corresponding Author

E-mail: nada.m.fahmy@gmail.com

INTRODUCTION

Tooth loss may be the cause in maxillary sinus pneumatization, which later result in fusion of the alveolar crest and floor of the sinus and in multiple cases, insufficient vertical bone volume and height (1). To overcome this constraint, several procedures have been developed: including tilted implants (2,3), zygomatic implants, (4) and short implants (5).

The usage of bone substitutes to improve vertical bone height in the floor of the maxillary sinus was first described by Boyne et al., (6). It is becoming more common to repair vertically resorbed ridges before implant placement to optimize implant fixation and future osseointegration (7,8).

To ensure a successful implant therapy, various sinus floor lift techniques have been tried to increase the

availability of bone in this location (9). Tanton (10) proposed the procedure in 1976, which involved surgical access gained to the sinus by entering the lateral wall of the maxillary zygomatic buttress followed by insertion of bone grafting substance (10). One of the common consequences of this approach was 35% of surgeries, is perforated maxillary sinus membrane (11,12).

Summers later improved the procedure by using compressive osteotomes and hand devices to lift the sinus membrane utilizing an alveolar approach to increase the alveolar ridge height (10,13). Even though this approach is more widely utilized and less intrusive than the lateral one, it has been found to have significant drawbacks. For example, the increased bone volume is restricted, and there is no direct visual control over the reliability of the Schneiderian membrane (14,15).

The direct sinus lift utilizing a balloon through a lateral window wall was described by Muroi et al., (16) in 2003, and Soltan et al., (17) in 2005. The membrane is gently detached with a latex balloon inflated with saline solution and inserted via a hole through the lateral wall of the sinus. In 2006, Kfir et al., (18) demonstrated a crestal sinus elevation utilizing the inflating balloon procedure, with placement of dental implants and bone grafts simultaneously in the same surgical step (9). It is, nonetheless, technically challenging, and cost-effective.

Vercellotti (19) in 2001 clarified an enhanced sinus elevation approach employing an ultrasonic surgical technique named piezoelectric bony window osteotomy to help in maxillary sinus surgery.

A physiological solution exposed to piezoelectric cavitation and piezoelectric elevators are adopted to elevate the Schneiderian membrane from floor of the sinus. Because of its surgical power of a functional frequency of 25-29 kHz, Piezoelectric internal sinus elevation has been shown to have good tactile sense (9,19) and limited bone cutting of just mineralized structures (20,21). Unlike previous transcrestal sinus lift procedures, this one is non-invasive. It is not dependable on compaction of the bone to lift the sinus membrane. The technique utilizing ultrasonic vibration together with hydraulic pressure to uplift the sinus membrane aided with vigorous irrigation may lead to breakage of the sinus floor. (22).

It has been reported that the hydrodynamic pressure applied to the membrane is uniformly dispersed because of its centrifugal direction, which causes the Schneiderian membrane to gradually detach (9,23).

Pressure applied to the membrane only placed to its top when employing osteotomes lift procedure followed by hand instruments, and while pressing upwards the whole membrane is subjected to ripping

stresses however it is not sufficiently raised in comparison to intralift sinus procedure (9,21,22,23).

Fewer trauma, reduced operation time, and a diminished risk of postoperative perforation and morbidity are all advantages of the transcrestal sinus floor elevation procedure in comparison to the lateral sinus floor elevation procedure (20,21,23).

Autografts, allografts, xenografts, alloplastic, and combining several grafting materials are commonly used in filling the new space created between the maxillary floor of the sinus and the raised membrane of the sinus (24). Due to the Schneiderian membrane's enhanced osteogenic capability, this is performed to retain available space for fresh bone growth, limit hematoma, and behave as a scaffold for endogenous bone regeneration. (24).

There have been numerous theories suggested to clarify how bone deposition might occur not including a graft (25). Cells obtained from the membrane of the sinus have the ability to flourish in cultural media, conveying osteoprogenitor cell markers, and osteogenic differentiation, in addition to new bone formation, which can be induced in the transplant region, according to Srouji et al. (26) Although formation of bone compels the migration and maturation of mesenchymal cells into osteoblasts, bone-forming cells may also be found in the periosteum of the raised sinus membrane (27)

Therefore, the goal of this study was to appraise the clinical and radiological outcomes of the minimally invasive transcrestal hydrodynamic piezoelectric sinus lifting procedure and the same exact outcomes of the conventional osteotomes lift.

The study's null hypothesis assumed that the transcrestal hydrodynamic piezoelectric sinus lifting method without bone graft will correspond the transcrestal hydrodynamic piezoelectric sinus lifting method with bone graft and the conventional osteotomes with a reduced risk of surgical trauma and membrane perforation.

MATERIALS AND METHODS

Ethical Considerations:

Ethical approval was acquired by the Ethical Committee of the Faculty of Dentistry, Alexandria University prior to the study and the participants elected were notified about the study's nature and informed consent was acquired.

Patients:

A sum of 30 maxillary sinuses of participants were indicated for maxillary sinus elevation followed by immediate placement of implants were involved in the study. The participants have been chosen from the Department of Oral and Maxillofacial Surgery outpatient clinic at Alexandria University's Faculty of Dentistry.

The maxillary sinuses of the participants were allocated into 2 study groups: study group A: 10 maxillary sinuses were elevated with the application of piezoelectric internal lifting kit for sinus boost without bone grafting and concurrent implant placement and study group B: 10 maxillary sinuses were elevated with the application of piezoelectric internal lifting kit for sinus boost with bone grafting and concurrent implant and one control group C: 10 maxillary sinuses were elevated using the conventional osteotomes technique with simultaneous implant placement.

Inclusion criteria

Patients of different genders from 30-50 years with one or more edentulous area in posterior maxilla requiring implants supported restorations, adequate oral hygiene and as calculated from the CBCT, a remaining height of bone between the crest of the alveolus and the floor of the sinus of not below than 5-7 mm is determined.

Exclusion criteria

Smokers, medically compromised patients, presence of infection, existing chemotherapy, or radiotherapy in facial region as well as pregnant women.

Materials

Piezoelectric intralift™ kit. (Acteon®) Manufactured by ACTEON® Group, France.) was used in this study. (Fig.1)

SuperLine Implant System (Dentium) (SuperLine dental implant, #214, 501 Gyeonggi R&DB Center, 105 Gwanggyo-ro, Yeongtong-gu, Suwon-si, Gyeonggi-do, Korea 443-270 Tel +82-31-888-5431 Fax +82-31- 888-5430 www.dentium.com.).

Standardized implant dimensions were placed 3.6×10 mm, in the edentulous maxillary area.

Sinus lift surgery osteotomes (Osteotome kit Dentium, 6731 Katella Avenue Cypress, CA 90630 Tel: 714-226-0229 Fax: 714-226-0019)

Bone graft Bonefill® (Bionnovation Biomedical A.B. Welandergatan 24 S-41656 Gothenburg Sweden Phone 0303773325)

Methods

I. Pre-surgical phase

A. Clinical examination

a) Inspection: To detect any swelling, asymmetry malocclusion, existence of any laceration, or draining sinuses.

b) Palpation: Palpation of the texture of mucosa labially and palatally and implant placement site.

B. Radiographic examination

A cone beam CT image was used to estimate the height of bone and the width between the floor of the

sinus and the crest of the alveolus, as well as implant size and positioning.

Surgical phase:

Every patient was operated under local anaesthetic with 4% articaine (1:100000 epinephrine, Novocol Pharmaceutical of Canada, Inc.) injected to the labial and palatal mucoperiosteum for pain control. For all groups, a horizontal mid-crestal incision was made and extended with a blade #15 through the attached gingival to some extent palatal to the crest of the ridge 3 mm, followed by dull elevation of the mucoperiosteal flap with a periosteal to expose the alveolar ridge both labially and palatally. Following a sequential drilling of Piezoelectric intralift tips from TKW1 to TKW4 to break the sinus floor with sterile saline irrigation (90-120ml/sec), the sinus was pushed upward by piezoelectric hydraulic pressure with the final TKW5 tip with sterile saline irrigation (30ml/sec), and the final drilling was done using the final drill of the implant, which was 3.4×10 mm conferring to the implant size yet to be placed 3.6×10 mm, and the implants were placed in the same way for both study groups A and B. (Fig.1) Before implant insertion, the study group B had their Bonefill® bone graft augmented. (Fig.2) For the control group C, an early osteotomy was performed with a pilot drill 1.7mm up to 1-2mm below the sinus floor, followed by sequential osteotomies drilling starting from the first drill 2.3mm then 2.8mm final drill to further broaden the osteotomy location to the required width. After gentle tapping with the osteotome 3.2mm to allow controlled breakage of the sinus cortical layer, the implant was inserted. (Fig.3) Regarding the 3 groups, cover screws were set down and interrupted sutures were used to relocate mucoperiosteal flap with the use of 3/0 black silk. (Fig.1,2)

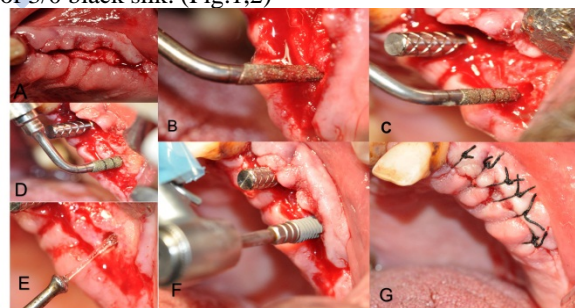


Figure (1): A) A mucoperiosteal flap elevation in the upper left posterior edentulous area in study group A. B) Pilot drilling with the TKW1 for cortical perforation. C) Drilling with the TKW2 for dropping into the sinus floor D) widening the osteotomy using TKW3 E) Sinus membrane detachment with the lifter drill TKW5 F) Implant placement G) Interrupted sutures.

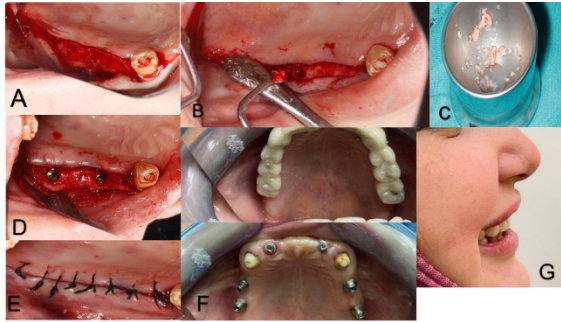


Figure (2): A) A mucoperiosteal flap elevation in the upper right posterior edentulous area for the study group B. B) Bone graft placement after the sequential drilling of the intralift Tips and before the implant. C) Bonefill®; Bone graft material used D) Implants placed and the cover screw over them E) Interrupted sutures F) A full arch upper bridge 6 months postoperatively has been inserted G) Profile view of the right side of the patient.

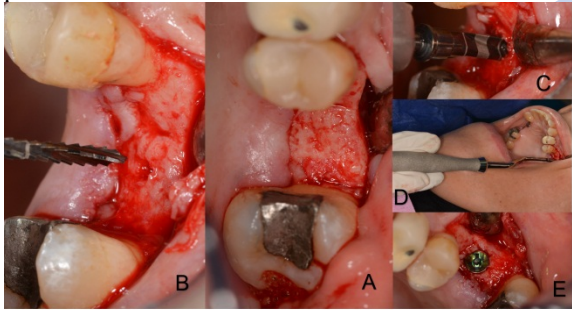


Figure (3): A) A transcrestal mucoperiosteal flap elevation and ridge exposure B) Pilot drilling with 1.7mm diameter drill in the control group C) Final drill corresponding the final osteotome 2.8mm D) Sinus membrane elevation with tapping on the osteotome size 3.2mm E) Cover screw in place.

II. Postsurgical phase

A. Postoperative instructions including:

Instructions were given to the participants to use icepacks extraorally hourly for the first day and to maintain daily oral hygiene routine, as well as a soft diet for the first week postoperatively.

Postoperative medications were prescribed to all participants including:

- Broad spectrum oral antibiotics : amoxicillin 875m / clavulanic acid 125mg (Augmentin 1gm Tablets, Medical Union Pharmaceuticals (MUP), GlaxoSmithKline, Cairo, Egypt) for a week with a dose of one capsule on a 12-hour basis.
- Non-steroidal anti-inflammatory drugs Ibuprofen 400 mg (Brufen tablet 400mg Abbott, Cairo, Egypt) around four days, at a dose of one tablet on a 8 hour basis.
- Warm 0.12% chlorhexidine gluconate solution (Hexitol mouth wash, Arab Drug Co., Cairo,

Egypt) as a mouthwash for 14 days for oral hygiene enhancement.

III. Follow up phase

A. Clinical evaluation

Every participant was checked clinically for any pain, edema, infection, or wound dehiscence after one week of the surgery.

B. Radiographic evaluation

A CBCT was requested directly after the surgery to verify the amount of elevation of sinus membrane. After 6 months, CBCT was requested again to measure bone height gained after sinus membrane elevation. (Fig.4)

C. Prosthetic phase:

Impressions were taken for all groups six months after sinus lifting and implant insertion. The final prosthesis was inserted, and the functional loading was employed on the Osseo-integrated implants. (Fig 2)

Statistical analysis of the data (28)

The IBM SPSS software programmer version 20.0 was used to analyze the data that was supplied to the computer. (IBM Corporation, Armonk, NY) (29) Number and percentage have been used to explain qualitative data. The Shapiro-Wilk test was utilized to ensure that the distribution was normal. Range (minimum and maximum), mean, median, standard deviation and interquartile range were utilized in describing quantitative data (IQR). The significance of the accomplished results was appraised at a 5 percent level.

The used tests were

1 - Chi-square test

For categorical variables, to compare between different groups

2 - Fisher's Exact or Monte Carlo correction

Correction for chi-square when more than 20% of the cells have expected count less than 5

3 - Marginal Homogeneity Test

Used to analyze the significance between the different stages

4 - F-test (ANOVA)

For normally distributed quantitative variables, to compare between more than two groups, and **Post Hoc test (Tukey)** for pairwise comparisons

5 - Paired t-test

For normally distributed quantitative variables, to compare between two periods

6 - ANOVA with repeated measures

For normally distributed quantitative variables, to compare between more than two periods or stages, and **Post Hoc test (Bonferroni adjusted)** for pairwise comparisons

RESULTS

A total of 30 maxillary sinuses were elevated in

patients presented with missing maxillary posterior teeth (unilateral or bilateral) and they were indicated for sinus lifting and implant placement.

There were no systemic disorders in any of the patients in this study, which could have impeded implant success.

The selected patients age ranged from 38.0 – 50.0 years in study group A with mean of 43.30 ± 4.35 years, from 37.0 – 59.0 in study group B with mean of 48.90 ± 6.69 and from 40.0 – 61.0 in group C with mean of 53.30 ± 6.86 . They were 16 females and 14 males. Implant sizes and type of missing teeth were standardized 3.5 x 10mm.

The alveolar height of the ridge from the crest of the margin to the maxillary sinus floor with the techniques used pre-operatively and after 6 months (Fig.4), as well as the clinical outcomes of pain and swelling intensity on the 2nd and 7th days postoperatively succeeding the surgeries, in accordance with the VAS scale, were predictors of the study.

I. Clinical results

Pain, edema, and infection

Pain have been monitored on the 2nd and 7th day following surgery utilizing the visual analogue scale. The VAS tool was 10 cm ruler displaying (0-1) no pain, (2-4) mild pain, (5-7) moderate pain and then to 10 intense pain (30).

On the 2nd day postoperatively in the study group A 4 patients experienced no pain (VAS=0-1), 7 patients experienced mild pain; 5 patients scored (VAS=2) and 2 patients scored (VAS=3) and no patients suffered any moderate to intense pain. On the 7th postoperative day the entire participants didn't feel any pain except for 1 patient was still experiencing mild pain scored (VAS=2). On the 2nd day postoperatively in the study group B 5 patients had no pain (VAS=0-1), 4 patients felt mild pain patients scored (VAS=2-4); 2 patients (VAS=2), 2 patients scored (VAS=3) and no patients experienced moderate to intense pain. On the 7th postoperative day, all patients had no pain except for one was still experiencing mild pain scored (VAS=3) experienced no pain (VAS=0) Concerning group C on the 2nd postoperative day only 1 patient had no pain, 7 patients faced mild pain; 6 patients recorded (VAS=3), 1 patient recorded (VAS=2) and 1 patient experienced a moderate pain scored (VAS=5). On the 7th day postoperatively 3 patients experienced no pain, 6 patients were still experiencing slight pain scored (VAS=2) and no patients suffered any moderately to severe pain. (Table 1)

Comparing the pain score between the two studied periods according to each group, there was a reduction in the pain record in the three of them, and there was a significant (p) value between the 2nd and 7th postoperative days in group A $p=0.014^*$

Evaluating between the three studied groups according to pain, at the 7th postoperative day, there wasn't a significant difference in between study groups A and B. But then comparing between study group A and control group C there was a statistic significancy at $p_2=0.017^*$ and a difference that is statistically significant at $p_3=0.050^*$ comparing in between group B with group C at the same period. (Fig 5)

Edema was measured postoperatively for all patients in the 2nd and 7th day postoperatively. On the 2nd day concerning group A; 3 patients suffered mild edema which was intraoral swelling confined to the surgical field which lasted for 2 days. On the 2nd day postoperatively in study group B; 4 patients suffered from mild edema which was extraoral confined to the surgical area, lasted for 4 days. On the 2nd day postoperatively in the control group C; 4 patients had a mild edema and 1 patient suffered from a moderate edema confined to the surgical area intraoral, extraorally extending to the lateral nasal side and infra-orbital that lasted for 3 days. All patients on the 7th day postoperatively had no edema present intraorally or extraorally.

Complications such as Schneiderian membrane perforation (SMP), bleeding, periimplantitis, and postoperative sinusitis were evaluated. Sinus membrane perforation didn't occur in any patient. No experienced epistaxis on the 1st day after surgery. No patients showed any signs of postoperative sinusitis or periimplantitis.

II. Radiographic evaluation

Assessment of volume of vertical bone height gained:

Vertical bone height of all implants was measured pre-operatively and six months after surgery. (Fig.4) The volume bone height was measured using OnDemand 3D™ as follow: (31).

- pical height gained was the difference between the lengths of vertical lines drawn and bisecting the horizontal line joining the crest of the buccal and palatal bone aspects (on a cross-sectional CBCT scan) and the sinus wall, preoperative and after 6 months.

When comparing between the three studied groups in accordance with the vertical bone height gained in each period (Table 2). In the pre-operative phase, concerning the study group A (table 2a) the mean bone height value was 6.62 ± 1.01 mm along with a lowest noted value of 4.39 mm and a highest noted value of 8.41 mm. Concerning the study group B in the same preoperative period, the mean vertical bone height value was 6.14 ± 0.66 mm with the lowest noted value of 5.25 mm and a highest noted value of 7.33 mm. Regarding the other control group C during the same preoperative phase, the mean vertical bone

height value was 6.69 ± 0.52 mm with a least noted value of 6.33 mm and a highest noted value of 7.96 mm. There wasn't any significance indicated between the groups in this pre-operative phase. At the 6th month, the mean vertical bone height estimation for group A was 11.96 ± 0.81 mm with a least noted value of 10.98 mm and a highest noted value of 13.32 mm. Including study group B in the same period, the mean vertical bone height value was 11.94 ± 0.67 mm with a least noted value of 10.87 mm and the highest noted value of 13.15 mm. The mean bone height value for control group C in the same sixth month phase was 10.40 ± 0.49 mm, with a lowest noted value of 9.88 mm and a highest noted value of 11.03 mm. (Table 2) These distinctions between groups after 6 months were significant, especially between group A and group C at $p < 0.001^*$ and study group B and control group C $p = 0.001^*$, respectively. Even though the difference between study groups A and B was not statistically significant. (Fig 6)

While comparing vertical bone height gained between the studied periods in each group pre-operatively and after 6 months, there was a great amount of bone gained in the mean value between the two studied periods in the study group A, with a mean value of (6.62 ± 1.01) at preoperative phase and a mean value of (11.96 ± 0.81) at the sixth month, that was highly statistically significant at $p < 0.001^*$. The quantity of the vertical bone height gained for the study group B also showed a noticeable increase with a mean value of (6.14 ± 0.66) at the preoperative phase and a mean value of (11.94 ± 0.67) after 6 months and this distinction was highly significant at $p < 0.001^*$. (Table 3) Concerning control group C at the preoperative phase the vertical bone height mean values were (6.98 ± 0.52) and raised to (10.40 ± 0.49) after 6 months. This variation was statistically highly significant at $p < 0.001^*$. (Fig 6)

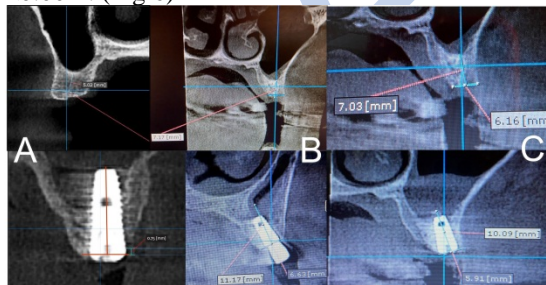


Figure (4): A) A cross-sectional CBCT indicating the difference of bone height obtained from the alveolar crest to the sinus floor, preoperatively and after 6 months for the first piezoelectric lift without bone graft B) A cross-sectional CBCT indicating the difference of the bone height obtained preoperatively and after 6 months for the other study group with bone grafting C) A cross-sectional CBCT indicating the difference of the bone

height obtained preoperatively and after 6 months for the control group C using osteotomes

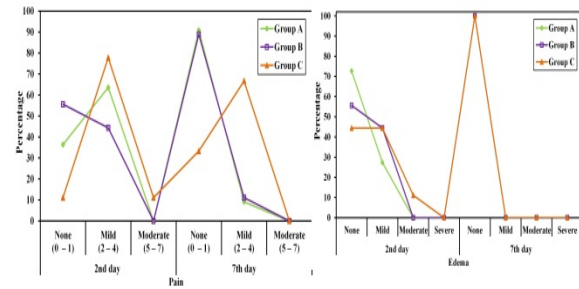


Figure (5): A) Pain and edema mean values obtained from the groups between the three different periods.

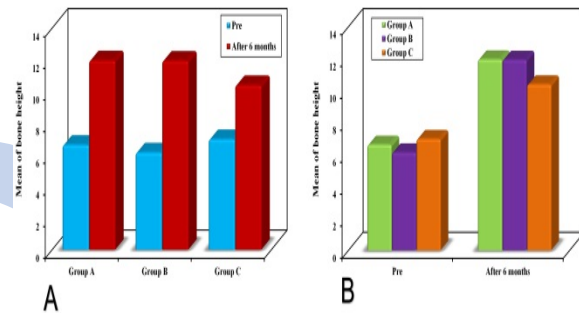


Figure (6): A) The two studied periods compared according to bone height in each group B) All groups compared according to bone height in each period

Table (1): All groups compared according to pain.

Table (1): Comparison between the three studied groups according to pain

Pain	Group A (n=11)		Group B (n=9)		Group C (n=9)		χ^2	MCp
	No.	%	No.	%	No.	%		
2nd day								
None (0 - 1)	4	36.4	5	55.6	1	11.1	5.307	0.215
Mild (2 - 4)	7	63.6	4	44.4	7	77.8		
Moderate (5 - 7)	0	0.0	0	0.0	1	11.1		
7th day								
None (0 - 1)	10	90.9	8	88.9	3	33.3	8.613*	0.008*
Mild (2 - 4)	1	9.1	1	11.1	6	66.7		
Moderate (5 - 7)	0	0.0	0	0.0	0	0.0		
Sig. bet. grps.	FE _{p1} =1.000, FE _{p2} =0.017*, FE _{p3} =0.050*							

χ^2 : Chi square test MC: Monte Carlo FE: Fisher Exact
 p: p value for comparing between the studied groups
 p₁: p value for comparing between Group A and Group B
 p₂: p value for comparing between Group A and Group C
 p₃: p value for comparing between Group B and Group C
 *: Statistically significant at $p \leq 0.05$

Table (2): All groups compared according to bone height in each period.

Table (2): Comparison between the three studied groups according to bone height in each period

Bone height	Group A (n = 11)	Group B (n = 9)	Group C (n = 9)	F	p
Pre					
Min. – Max.	4.39 – 8.41	5.25 – 7.33	6.33 – 7.96		
Mean ± SD.	6.62 ± 1.01	6.14 ± 0.66	6.98 ± 0.52	2.624	0.092
Median (IQR)	6.70 (6.23 – 7.0)	6.02 (5.85 – 6.39)	6.95 (6.55 – 7.12)		
After 6 months					
Min. – Max.	10.98 – 13.32	10.87 – 13.15	9.88 – 11.03		
Mean ± SD.	11.96 ± 0.81	11.94 ± 0.67	10.40 ± 0.49	15.989*	<0.001*
Median (IQR)	11.98 (11.21 – 12.26)	12.03 (11.61 – 12.30)	10.10 (10.02 – 11.01)		
Sig. bet. grps.	p ₁ =0.997, p ₂ <0.001*, p ₃ <0.001*				

IQR: Inter quartile range SD: Standard deviation
 F: F for ANOVA test, pairwise comparison bet. each 2 groups was done using Post Hoc Test (Tukey)
 p: p value for comparing between the studied groups
 p₁: p value for comparing between Group A and Group B
 p₂: p value for comparing between Group A and Group C
 p₃: p value for comparing between Group B and Group C
 *: Statistically significant at p ≤ 0.05

Table (3): The two studied periods compared according to bone height in each group.

Table (3): Comparison between the two studied periods according to bone height in each group

Bone height	Pre	After 6 months	t	p
Group A (n = 11)				
Min. – Max.	4.39 – 8.41	10.98 – 13.32		
Mean ± SD.	6.62 ± 1.01	11.96 ± 0.81	15.387*	<0.001*
Median (IQR)	6.70 (6.23 – 7.0)	11.98 (11.21 – 12.26)		
Group B (n = 9)				
Min. – Max.	5.25 – 7.33	10.87 – 13.15		
Mean ± SD.	6.14 ± 0.66	11.94 ± 0.67	17.612*	<0.001*
Median (IQR)	6.02 (5.85 – 6.39)	12.03(11.61 – 12.30)		
Group C (n = 9)				
Min. – Max.	6.33 – 7.96	9.88 – 11.03		
Mean ± SD.	6.98 ± 0.52	10.40 ± 0.49	20.966*	<0.001*
Median (IQR)	6.95 (6.55 – 7.12)	10.10 (10.02 – 11.01)		

IQR: Inter quartile range SD: Standard deviation t: Paired t-test
 p: p value for comparing between Pre and After 6 months
 *: Statistically significant at p ≤ 0.05

DISCUSSION

Sinus lifting is a frequent surgical procedure that raises the bone volume within the floor of the maxillary sinus for implantation. Particularly after the pneumatization of the sinus cavity headed to a loss of bone height vertically. The elevation and lifting of the sinus membrane, as well as the gluing of bone substitutes, has been commonplace in past years (32). This operation can be conducted in a variety of ways. It makes use of vibrations for clean cutting and precise incisions (20).

According to several studies (8,9,15,19,20,22), using piezoelectric surgery decreases the threat of sinus membrane tear. The outcomes of this investigation demonstrated that neither the piezoelectric intralift nor the traditional osteotomes caused penetration of the Schneiderian membrane this probably due to the little sample size and performing the surgery through a transcrestal approach rather than the lateral window. These conclusions matched those of Rador et al. (33) and Troedhan et al. (21) research.

The technical abilities of piezoelectrical surgery may well be the explanation for this disparity. Piezoelectric devices may well cut extremely calcified bone owing to their surgical power as its piezoelectrical handpiece has an effective frequency of 25 to 29 kHz is three times that of ordinary ultrasound (34).

In the existing study, piezoelectric intralift surgical procedure and conventional osteotomes were utilized to reduce morbidity and surgical stress when uplifting the maxillary sinus floor, a transcrestal technique rather than a lateral method was taken in consideration, which may agree with Catros et al. (23). Mohan et al. (8) conducted a study; evaluating the novel of transcrestal hydrodynamic piezoelectric internal elevation with the traditional osteotomes through a lateral window technique(LWO) and found that the piezoelectric intralift one was more likely than the conventional surgical mallet and osteotomes in relation to time consumption, membrane perforation, postoperative morbidity, as the piezoelectric internal sinus lift can prevent potential thermal damage and allow a very low rate of membrane perforation and painkiller consumption for the patient (8). Which agreed with the conclusions of this study.

In related research, Llopet et al. (35) ended up finding that the success rate of membrane elevation using the hydrodynamic transalveolar approach was higher than that of the conventional transcrestal osteotomes technique, thus because TKW5 tip of the intralift kit proceeded as a piston owing to the concise socket wall organization, the sinus membrane acted as a valve and water from the vigorous irrigation serving mutually as a seal and hydraulic medium (34).

About the hydrodynamic piezoelectric internal sinus elevation without any bone grafting, bone regeneration was evident radiographically along the implant body. It's encouraged by means of a study done by Srouji et al. (26) in a vivo and in vitro study showed testimony for the presence of osteoprogenitor cells within the Schneiderian membrane which induces new bone formation and with Cara-Fuentes et al. (27) that observed bone reformation in the new slot established beneath the raised Schneiderian membrane using a full thickness transalveolar technique without the use of bone grafts.

According to this study, pain and edema in both piezoelectric surgery groups were substantially reduced on the 7th postoperative day compared to the 2nd day, with 36.4 % of study group A on the 2nd day post-operatively suffering pain and 90.9 percent feeling no pain on the seventh day postoperatively. When comparing reduction in pain between both piezoelectric surgery groups and the conventional control group on the seventh postoperative day, there

was statistical significance. These discoveries matched those of Rickert, Kotrikova, and Landes et al (36,37,38).

In fact, because piezosurgery uses micro-vibrations rather than the macro-vibrations and noise generated by traditional surgical burs and osteotomes, it emits less vibration and noise (8,9,15,22,24,33). This makes the piezo system easier to use and gives the surgeon more control over the procedure (8).

This contradicted the findings of a double-blinded split mouth randomized trial conducted by Shahakbari et al. (39) who claimed that piezosurgery's biggest flaw is the time issue. The piezo group's mean surgical time (240.23 ± 49.5 s) was considerably slower than the osteotomes group's (135.17 ± 43.53 s) ($P < 0.001$). Therefore, there was no noticeable statistical significance in clinical terms, pain and edema on the 2nd and 7th days following surgery (31). Jiang et al. (39) completed a meta-analysis of randomized clinical trials and discovered that although piezosurgery intralift takes longer than rotating tool surgery, it is associated with less postoperative problems such as discomfort and swelling (38). Which approved that the piezosurgery intralift still works well despite the time constraint.

The initial bone height was meant to be more than four mm but less than eight mm from the crest of the alveolar bone to the maxillary floor of the sinus. This remains supported by research by Llopet et al. (34), who advocated a residual bone height of 9mm for single-stage procedures to avoid compromising initial implant stability and to enhance implant survival predictability (40).

Related to this research the use of the piezoelectric intralift method and the conventional osteotomes resulted in a significant bone height gaining in both, but the piezoelectric intralift method in both study group (A) and (B) showed higher significance in the sinus floor augmentation on the postoperative CBCT with mean values in the study group (A) were 6.62 ± 1.01 preoperatively and 11.96 ± 0.81 after 6 months, mean values in the study group (B) were 6.14 ± 0.66 and 11.94 ± 0.67 respectively, compared with osteotomes technique of control group (c) of mean values 6.98 ± 0.52 preoperatively and 10.40 ± 0.49 after 6 months.

This agreed with the radiographic postoperative results of Catros et. (23) in which the CT scan observations postoperatively revealed; the mean sinus floor fill up was 13 ± 0.85 mm in height, 10.57 ± 0.94 mm in mesio-distal direction and 11.6 ± 1.02 mm in bucco-palatal direction utilizing the Intralift procedure. Along with the mean sinus floor using summers lifting method that was 9.87 ± 0.67 mm in height, 9.3 ± 0.79 mm in bucco-palatal direction, and 9.9 ± 1.29 mm in mesio-distal direction. When

compared to the Summers technique, the hydrodynamic intralift technique developed much higher sinus floor augmentation in both buccopalatal and mesiodistal directions in this investigation ($P < 0.001$) (23).

Indeed, this study found that the transalveolar hydrodynamic internal sinus lift is a more predictable way for augmentation of severely resorbed maxillary sinuses with a significant difference for the bone volume gained and less postoperative problems; pain and edema and membrane perforation comparing to the traditional osteotomes procedure, which rejected the study's null hypothesis.

Limitations and suggestions:

1. The sample size was woefully insufficient to understand the critical relationship among variables and their significance.
2. A longer follow-up phase of up to 1 or 2 years is required to determine the bone density around the implant, which is an important outcome to consider.

CONCLUSIONS

In the scope of this study's restrictions, the subsequent findings can be:

1. Piezoelectric surgery clinical outcomes were better than the conventional osteotomes.
2. Effect of the hydraulic intralift on bone volume gained is definite and great.

CONFLICT OF INTREST

The authors acknowledged that they haven't any conflict of interest.

FUNDING:

The authors obtained no precise funding for this work.

REFERENCES

1. Lim HC, Kim S, Kim DH, Herr Y, Chung JH, Shin SI. Factors affecting maxillary sinus pneumatization following posterior maxillary tooth extraction. *J Periodontal Implant Sci.* 2021 Aug; 51:285-95.
2. Amid, R., Kadkhodazadeh, M., Moscowchi, A. et al. Effect of Schneiderian Membrane Thickening on the Maxillary Sinus Augmentation and Implantation Outcomes: A Systematic Review. *J. Maxillofac. Oral Surg.* 2021; 2:534-44.
3. Cooper LF, De Kok IJ, Thalji G, Bryington MS. Prosthodontic Management of Implant Therapy: Esthetic Complications. *Dent Clin North Am.* 2019; 63:199-216.
4. Chrcanovic BR, Albrektsson T, Wennerberg A. Survival and Complications of Zygomatic Implants: An Updated Systematic Review. *J Oral Maxillofac Surg.* 2016 Oct; 74:1949-64.

5. Esposito M, Barausse C, Pistilli R, Sammartino G, Grandi G, Felice P. Short implants versus bone augmentation for placing longer implants in atrophic maxillae: One-year post-loading results of a pilot randomised controlled trial. *Eur J Oral Implantol*. 2015 Autumn; 8:257-68.
6. Boyne PJ, James RA. Grafting of the maxillary sinus floor with autogenous marrow and bone. *J Oral Surg*. 1980 Aug; 38:613-6.
7. Shenoy S B, Talwar A, Thomas B, Ramesh A, Vamsi A R. (2020). Direct vs Indirect Sinus Elevation: A Literature Review. *MJDS* 5, 15-2
8. Mohan Wang, Jiakai He, Xin Liu. Maxillary Sinus Floor Elevation Using the Lateral Window Osteotomy Versus Crestal Window Technique with Endoscopy and Hydraulic Pressure. *Acta Microscopica*. 2020; 29(2):642-49.
9. Lafzi A, Atarbashi-Moghadam F, Amid R, Sijanivandi S. Different techniques in transalveolar maxillary sinus elevation: a literature review. *J Adv Periodontol Implant Dent*. 2021;13: 35-42.
10. Tatum H Jr. Maxillary and sinus implant reconstructions. *DentClin North Am* 1986; 30:207-29.
11. Nkenke E, Schlegel A, Schultze-Mosgau S, Neukam FW, Wiltfang J. The endoscopically controlled osteotome sinus floor elevation: a preliminary prospective study. *Int J Oral Maxillofac Implants* 2002; 17:557-66.
12. Stricker A, Voss PJ, Gutwald R, Schramm A, Schmelzeisen R. Maxillary sinus floor augmentation with autogenous bone grafts to enable placement of SLA-surfaced implants: preliminary results after 15-40 months. *Clin Oral Implants Res* 2003; 14:207-12.
13. Summers RB. Sinus floor elevation with osteotomes. *J Esthet Dent* 1998; 10:164-71.
14. Summers RB. A new concept in maxillary implant surgery: the osteotome technique. *Compendium* 1994; 15:152-4.
15. Vitkov L, Gellrich NC, Hannig M. Sinus floor elevation via hydraulic detachment and elevation of the Schneiderian membrane. *Clin Oral Implants Res* 2005; 16:615-21.
16. Muronoi M, Xu H, Shimizu Y, Ooya K. Simplified procedure for augmentation of the sinus floor using a haemostatic nasal balloon. *Br J Oral Maxillofac Surg* 2003; 41:120-1.
17. Soltan M, Smiler DG. Antral membrane balloon elevation. *J Oral Implantol* 2005; 31:85-90.
18. Kfir E, Kfir V, Kaluski E, Mazor Z, Goldstein M. Minimally invasive antral membrane balloon elevation for single-tooth implant placement. *Quintessence Int* 2011; 42:645-50.
19. Vercellotti T, De Paoli S, Nevins M. The piezoelectric bony window osteotomy and sinus membrane elevation: introduction of a new technique for simplification of the sinus augmentation procedure. *Int J Periodontics Restorative Dent* 2001; 21:561-7.
20. Barone A, Santini S, Marconcini S, Giacomelli L, Gherlone E, Covani U. Osteotomy and membrane elevation during the maxillary sinus augmentation procedure. A comparative study: piezoelectric device vs. conventional rotative instruments. *Clin Oral Implants Res* 2008; 19:511-5.
21. Troedhan A, Kurrek A, Wainwright M. Biological principles, and physiology of bone regeneration under the Schneiderian membrane after sinus lift surgery: a radiological study in 14 patients treated with the transcresal hydrodynamic ultrasonic cavitation sinus lift (Intralift). *Int J Dent* 2012; 2012:576238.
22. Troedhan A, Kurrek A, Wainwright M, Jank S. Schneiderian membrane detachment using transcresal hydrodynamic ultrasonic cavitation sinus lift: A human cadaver head study and histologic analysis. *J Oral Maxillofac Surg* 2014; 72:1503. e1-10.
23. Catros S, Montaudon M, Bou C, Da Costa Noble R, Fricain JC, Ella B. Comparison of conventional transcresal sinus lift and ultrasound-enhanced transcresal hydrodynamic cavitation sinus lift for the filling of sub antral space: A human cadaver study. *J Oral Implant* 2015; 41:657-61.
24. Kemprij J, Sundaram SS, Doss GP, Nakeeran KP, Raja VK. Maxillary Sinus Augmentation Using Xenograft and Choukroun's Platelet-Rich Fibrin as Grafting Material: A Radiological Study. *J Maxillofac Oral Surg* 2019;1-6.
25. Spinelli D, DE Vico G, Condò R, Ottria L, Arcuri C. Transcresal guided sinus lift without grafting materials: a 36-month clinical prospective study. *Oral Implantol* 2016; 8:74-86.
26. Srouji S, Kizhner T, Ben David D, Riminucci M, Bianco P, Livne E. The Schneiderian membrane contains osteoprogenitor cells: in vivo and in vitro study. *Calcif Tissue Int* 2009; 84:138-45
27. Cara-Fuentes M, Machuca-Ariza J, Ruiz-Martos A, Ramos-Robles MC, Martínez-Lara I. Long-term outcome of dental implants after maxillary augmentation with and without bone grafting. *Med Oral Patol Oral Cir Bucal* 2016;21: e229-35.
28. Kotz S, Balakrishnan N, Read CB, Vidakovic B. *Encyclopedia of statistical sciences*. 2nd ed. Hoboken, NJ: Wiley-Interscience; 2006.

29. Kirkpatrick LA, Feeney BC. A simple guide to IBM SPSS statistics for version 20.0. Student ed. Belmont, Calif.: Wadsworth, Cengage Learning; 2013.
30. Johnson C. Measuring Pain. Visual Analog Scale Versus Numeric Pain Scale: What is the Difference? *J Chiropr Med* 2005; 4:43-4.
31. Song DS, Kim CH, Kim BJ, Kim JH. Tenting effect of dental implant on maxillary sinus lift without grafting. *J Dent Sci.* 2020 Sep;15(3):278-285.
32. Li J, Lee K, Chen H, Ou G. Piezoelectric surgery in maxillary sinus floor elevation with hydraulic pressure for xenograft and simultaneous implant placement. *J Prosthet Dent* 2013; 110:344-8.
33. Shao J, Zhang Y, Qing H, Li L. An alternative approach to transalveolar sinus elevation for the placement of multiple implants. *J Prosthetic Dent* 2019.
34. Monje A, Diaz KT, Aranda L, Insua A, Garcia-Nogales A, Wang HL. Schneiderian membrane thickness and clinical implications for sinus augmentation: a systematic review and meta-regression analyses. *J Periodontol.* 2016; 87:888–99.
35. Llopet J, Montaudon M, Guillaud E, Ella B. Comparison of 2 crestal sinus floor lift techniques performed on human cadavers. *Implant Dent* 2014;1; 23:626-32.
36. Rickert D, Vissink A, Slater JJ, Meijer HJ, Raghoebar GM. Comparison between conventional and piezoelectric surgical tools for maxillary sinus floor elevation. A randomized controlled clinical trial. *Clin Implant Dent Relat Res.* 2013 Apr; 15:297-302.
37. Kotrikova B, Wirtz R, Krempien R, Blank J, Eggers G, Samiotis A et al (2006) Piezosurgery—a new safe technique in cranial osteoplasty? *Int J Oral Maxillofac Surg* 35:461–65.
38. Landes CA, Stübinger S, Rieger J, Williger B, Ha TK, Sader R. Critical evaluation of piezoelectric osteotomy in orthognathic surgery: operative technique, blood loss, time requirement, nerve and vessel integrity. *J Oral Maxillofac Surg.* 2008 Apr;66(4):657-74.
39. Shahakbari, R., Labafchi, A., Salami, S. et al. Piezotome Versus Surgical Bur: Which is More Effective in Reducing the Postoperative Pain and Edema Following Open Sinus Lift Surgery? *J. Maxillofac.OralSurg.* 20, 642–48(2021).
40. Jiang Q, Qiu Y, Yang C, Yang J, Chen M, Zhang Z. Piezoelectric Versus Conventional Rotary Techniques for Impacted Third Molar Extraction: A Meta-analysis of Randomized Controlled Trials. *Medicine (Baltimore).* 2015 Oct;94: e1685.