

# EVALUATION OF COMPUTER-GUIDED LOW WINDOW LATERAL SINUS LIFT TECHNIQUE

Nada A. Elwatidy<sup>1\*</sup> BDS, Nagy H. El Prince<sup>2</sup> PhD, Riham M. Fliefel<sup>3</sup> PhD

## ABSTRACT

**INTRODUCTION:** The introduction of computer guided surgery in implant dentistry has marked a new era allowing various procedures to be performed with a great level of precision and accuracy. Recently, a novel design of the lateral window osteotomy, the “Low Window” sinus lift technique, was proposed to facilitate sinus augmentation and reduce postsurgical patient discomfort.

**AIM OF THE STUDY:** The aim of this study was to evaluate the safety and effectiveness of the “Low Window” lateral sinus lifting technique.

**MATERIALS AND METHODS:** The study group included 12 patients that were treated using the low window lateral sinus lift technique with simultaneous implant placement. This was facilitated using a Three dimensional (3D) printed surgical guide. Assessment on postoperative pain, edema, implant stability, vertical bone height gain, and complications such as Schneiderian membrane perforation.

**RESULTS:** All patients experienced mild pain postoperatively with a significant decrease in pain from the 1st to 3rd day. Sinus membrane perforation occurred in 2 patients as well as mild postoperative bleeding on the first day. A statistically significant increase in vertical bone height ( $p < 0.001$ ) was observed as well as in implant stability, while marginal bone loss was within normal limits.

**CONCLUSION:** The use of computer guided low window lateral sinus lift technique resulted in a satisfactory outcome in terms of postoperative pain, edema, bleeding, sinus perforation rates, implant stability, vertical bone height gained and marginal bone loss.

**KEYWORDS:** Guided surgery, Lateral sinus lift, Schneiderian membrane perforation, Sinus augmentation.

**RUNNING TITLE:** Computer-guided Low Window lateral sinus lift technique

**CLINICAL TRIAL REGISTRATION:** NCT04618588

---

<sup>1</sup> Bachelor of Dental Surgery, Faculty of Dentistry, Alexandria University, Alexandria, Egypt.

<sup>2</sup> Professor of Oral and Maxillofacial Surgery Alexandria University, Alexandria, Egypt.

<sup>3</sup> Lecturer at the Oral and Maxillofacial Surgery Department, Faculty of Dentistry, Alexandria University, Alexandria, Egypt.

*\*Corresponding author:*

*E-mail:* [nadaelwatidy@hotmail.com](mailto:nadaelwatidy@hotmail.com)

## INTRODUCTION

Implant placement in the posterior maxilla is complicated by insufficient bone volume due to bone resorption following extraction, continuous pneumatization of the maxillary sinus and reduced quality of residual bone. Sinus augmentation is a well-recognized technique designed for facilitating rehabilitation of the atrophic posterior maxilla (1,2).

Sinus augmentation has been universally accepted since it was primarily introduced by Tatum (3) Boyne and James (4) and has been researched extensively since then (5, 6). Modifications such as the crestal approach employed by Summers (6) and several other authors (7,8) in effort to be more conservative and to lower the rate of complications. Although the crestal approach is less invasive, the amount of bone and access gained are less and requires a minimum of 6 mm crestal bone height to achieve primary stability of the implant. Therefore, a lateral approach is still indicated in cases with advanced alveolar bone atrophy (8).

The location and design of the lateral bone window determine the mucoperiosteal flap design (8). The window shape, width, height, and distance from the alveolar crest impact the direction that the instruments must undertake to successfully elevate the membrane from the sinus floor (9).

Accordingly, this affects the probability of membrane perforation, one of the most common sinus augmentation complications. Moreover, the degree to which the mucoperiosteal flap is retracted can easily limit access to the operatory field because of the need to keep the patient's vestibular tissues retracted for a longer time causing patient discomfort and operator fatigue. Indications concerning the window size vary from author to author (10). Different authors suggest that the lower antrotomy line should be positioned either flush with the sinus floor or up to 2- 3 mm above it (11, 11). Recently, Zaniol T et al., (9) have proposed a design that involves positioning the window as low and mesial as possible called the “Low Window Sinus Lift technique”.

The “Low Window” is designed with the aid of computer guided technology allowing the surgeon to easily access and elevate the mesial portion of the sinus membrane and eliminate any residual bone wall that could slow down the membrane elevation thus limiting the invasiveness of the procedure and saving the operator time. Furthermore, it prevents unnecessary distal extension of both the mucoperiosteal flap and the bone window (9).

Elwatidy et al.

So far, no prospective evaluation of the effectiveness and safety of the "low window" design on complication rates or effort needed to carry out sinus lift surgeries has been carried out.

The aim of this study is to evaluate the safety and effectiveness of the "Low Window" lateral sinus lifting technique.

## MATERIALS AND METHODS

Appropriate ethical clearance was obtained from the ethical committee of Alexandria Dental University and the patients had signed a written informed consent (IRB NO: 00010556-IOG 0008839). This study was a prospective case series conducted on patients selected from the outpatient clinic of the Oral and Maxillofacial Surgery Department, Faculty of Dentistry, Alexandria University. All patients met the inclusion criteria, signed an informed consent before going undergoing the guided low window lateral sinus floor elevation with simultaneous implant placement. This study is registered in the archives of ClinicalTrials.gov under the registration number: NCT04618588. The study was reported according to the STROBE guidelines (12).

### Patients

Sample size was estimated based on the following assumptions: confidence interval = 95%, study power = 80%, Out of 10 maxillary sinus floor elevations in the computer guided group of patients, Schneiderian membrane was successfully elevated in 90%, while perforation occurred in only 10% of the cases. (13) Using these assumptions, the repeated sample size was calculated using G power 3.0.10 to be the 10 patients increased to 12 patients to make up for loss to follow up. (14)

Twelve patients have been included in this study requiring rehabilitation of the posterior maxilla, with an age range of 32-57 years with no gender predilection that agreed to present for follow-up visits for a minimum postoperative period of six months. Patients inclusion criteria: (a) patients requiring implant placement in the posterior maxilla (Kennedy Classification: Class 1 and Class 2), (b) tooth extractions at the implant sites which were performed at least 4 months before surgery, (c) residual bone height between the alveolar bone crest and the sinus floor ranges from 4 to 6 mm. Patients were excluded if they (a) were medically compromised contradicting the surgery, (b) heavy smokers, (c) have maxillary sinus pathologies, (d) acute oral infections or (e) received recent chemo or radiotherapy

### Methods

Presurgical assessment of each patient was performed. Demographic data such as name, age, sex, occupation, address, phone number was gathered followed by a detailed medical and dental history. Intraoral examination of the patient's dentition, residual bone and periodontal health was also evaluated.

Preoperative impressions were taken and study models were mounted to evaluate the relation between maxillary and mandibular arches. Orthopantomogram (OPG) and cone beam computer tomography (CBCT) of the targeted areas were also done in order to evaluate residual bone height between the alveolar bone crest and the sinus floor, residual ridge width, bone quality and planning the number, size and position the implants.

Designing the surgical guide was performed using In2Guide™ system (Cybermed Inc., CA, USA). CBCT images

Computer-guided Low Window lateral sinus lift technique of the patient's maxilla (Vatech green CT, USA) was saved as a Digital imaging and communications in medicine (DICOM) file. stereolithography (STL) file of the bone structure is extracted from the DICOM file on which the surgical guide is designed using Exocad software (exocad, GmbH, Germany). The low window design was planned where the lower osteotomy line will be flushed with the floor of the sinus, the upper osteotomy line is 6 mm above the lower line, the mesial line is flushed with the anterior wall and the distal line will correspond to the position of the most distal implant (Figure 1(a-d)) (9).

The planned surgical guide was then transferred to the 3D printer machine (EnvisionTEC DDP, EnvisionTEC GmbH, Germany) using OnDemand3D™ program and fabricated using Eshell 300 liquid photo-reactive acrylate (EnvisionTEC GmbH, Germany). The resin was applied in layers of 0.25-0.1 microns and are dried sequentially (Figure 1(e-f)).

Patients were instructed to rinse with 0.125% chlorhexidine antiseptic mouth-wash for 2 minutes prior to surgery. The surgical area was anesthetized with local anesthesia. (Articaine hydrochloride 40 mg/ml with adrenaline 0.01 mg/ml). Infraorbital and greater palatine nerve blocks and local infiltration were given in order to properly anesthetize the area. A crestal incision was made in the posterior edentulous area followed by a vertical incision made at 45 degrees distal to the most anterior tooth. A full thickness mucoperiosteal flap was elevated at the surgical site enabling the apical osteotomy line to be drawn at a distance of 6mm above the residual bone height from the ridge. The customized surgical guide was secured in its proper position. After drilling, the anchor pin was placed in the prepared place. (Figure 2-a). Using the standardized piezoelectric tip (SL1) (Sinus lift kit, ACTEON® Group, France) with sterile saline irrigation, the outline of the window in the lateral maxillary sinus wall was formed.

The bone window was thinned down using the specialized DASK drill #4 and #5 from the DASK Kit (Dentium Co.,Ltd, South Korea ) until the grey shadow of the sinus membrane became visible. The sinus membrane at the circumference of the bony window was detached using the dome-shaped Sinus Membrane Elevator (XSE1L). Sinus membrane elevators (XSE2L), (XSE3L) and (XSE4L) were used to carefully lift the sinus membrane from the floor and anterior wall of the sinus to create adequate space for graft material (Figure 2-b). The membrane was further elevated to the medial wall in order to provide additional blood supply from that bone. The implants were drilled in the positions indicated by the surgical guide (Figure 2-c). Half the amount of the xenograft (Bonefill®, Bionnovation Biomedical, Brazil) was introduced into the cavity followed by insertion of the dental implants. The dental implants (Dentium Co., Ltd, Seoul, South Korea) were placed at torque 30~45N·cm. Stability of the implants was measured using an implant stability meter (Osstell ISQ, Osstell, Gothenburg, Sweden) (15).

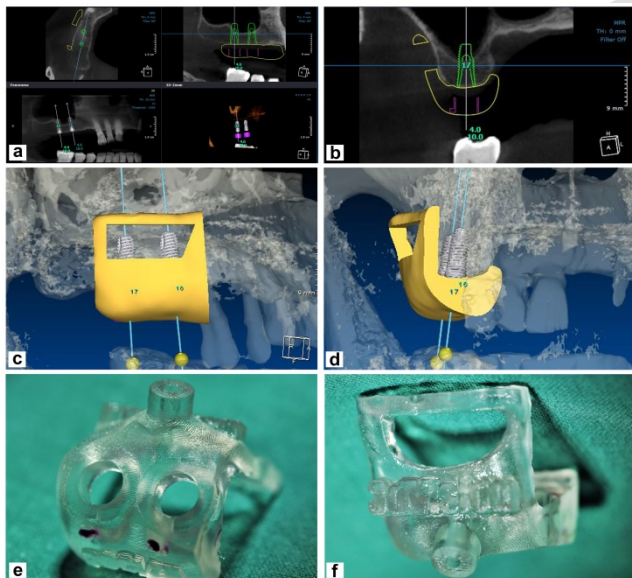
Filling the cavity with the rest of the xenograft was completed after implant placement(s). The size of the collagen membrane (T-Gen, Alpha-Bio Tec Ltd., Korea) was adjusted to match the size of the lateral bone window and then placed and stabilized by the cover screw. The flap was released by short horizontal cuts in the inner surface of the mucosa to provide a tension free flap. This was followed by closure of the flap with water tight sutures (horizontal mattress with a single interrupted

in the center) using 3/0 silk suture material (GMS, Alexandria, Egypt).

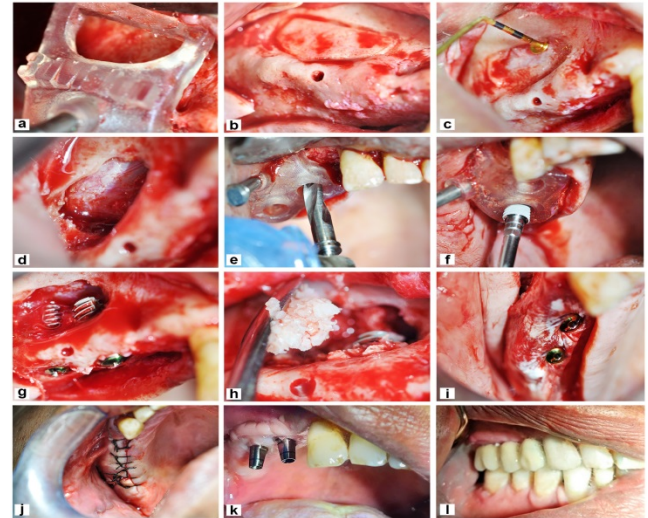
After 6 months from the operation, a small incision was made directly over the implant and the cover screw was removed. Implant stability was measured again using the Osstell device. The abutment was placed at torque 25~30 N.cm. An impression was taken and sent to the lab for fixed prosthetics construction. The fixed prosthesis was cemented using glass ionomer cement. The outcomes to be measured are: pain, edema, postoperative complications such as bleeding and Schneiderian membrane perforation, bone density, vertical bone height, implant stability and marginal bone loss.

#### Statistical analysis

Data were analyzed using IBM SPSS software package version 20.0. (Armonk, NY: IBM Corp). Qualitative data were described using number and percent. The Kolmogorov-Smirnov test was used to verify the normality of distribution. Quantitative data were presented as mean and standard deviation. The used tests were: Paired t-test, Wilcoxon signed ranks test and Friedman test. Significance of the obtained results was measured at  $p < 0.05$  or  $p < 0.001$ .



**Figure 1:**(a-b) Preoperative CBCT view showing designing of stent and planning of implant positions (c-d) Designing stage of the 3D printed surgical stent (e-f) Customized stereolithographic stent after fabrication showing both the lateral window and implant guides.



**Figure 2:** Showing a full case presentation (a) Adaptation of surgical guide and fixation with anchor pin (b) Outline of osteotomy with piezoelectric tip (SL1) (c) Detaching sinus membrane using sinus membrane elevator (XSE1L) (d) Schneiderian membrane after elevation (e) Drilling of implant (f) Implant placement (g) View of both implants stabilized with the sinus elevated (h) Placement of xenograft material into the sinus cavity (i) Stabilization of collagen membrane using the cover screw (j) Suturing using 3/0 silk (k) Abutment placement (l) Prosthesis fixation.

## RESULTS

A total of 12 patients were presented with missing maxillary posterior teeth (unilateral or bilateral free end-saddle) indicated for sinus lifting and implant placement. The selected patients' age was ranged between 32-57 years with mean of 46.42 years, 8 of them were males and 4 were females. A total of 19 implants were placed.

Pain was monitored for 5 days after surgery using the Visual Analogue Scale (VAS) (15). On the first day postoperatively, all patients experienced mild pain. 6 patients scored (VAS=2), 2 patients (VAS=1) and 4 patients experienced no pain (VAS=0). On the second day, 6 patients scored (VAS=1) and 6 experienced no pain (VAS=0). The average pain score of the 3 days was  $0.63 \pm 0.46$ . (Table 1)

Edema was measured postoperatively for all patients in the 1st week (16). This was assessed in the 1st week postoperatively and measured as follows:(a) None (no inflammation), (b) Mild (intraoral swelling confined to the surgical field), (c) Moderate (extraoral swelling in the surgical zone) (d) Severe (extraoral swelling spreading beyond the surgical zone).

On the 3rd day, 10 patients experienced mild edema which is intraoral swelling confined to the surgical field while 2 patients experienced moderate edema which is extraoral edema confined to the surgical area. (Table 2) Both intraoperative and postoperative complications such as Schneiderian membrane perforation, bleeding, periimplantitis and postoperative sinusitis were evaluated. Sinus membrane perforation occurred in two patients and two patients experienced epistaxis on the 1st day after surgery. No patients showed any signs of postoperative sinusitis or periimplantitis. (Table 2)

Implant stability was checked for all implants using Osstell, immediately postoperative and after 6 months. The mean ISQ recorded postoperatively was  $69.79 \pm 8.10$  where the minimum ISQ number was 64 and maximum ISQ number was 97. The mean ISQ recorded after 6 months was  $75.47 \pm 3.22$  where the minimum ISQ number was 70 and the maximum recorded ISQ number was 79. (Table 3)

The mean bone density recorded postoperatively was  $600.4 \pm 226.0$  HU where the minimum bone density value was 386.9 HU and maximum bone density value was 1226.3 HU. The mean bone density recorded after 6 months was  $552.4 \pm 164.9$  HU where the minimum bone density value was 316.4 HU and the maximum recorded bone density value was 953.6 HU. There was no statistically significant between the preoperative and postoperative bone density ( $p=0.107$ ). (Table 3)

Preoperative residual bone heights ranged between 4.34 and 6.0 mm with a mean residual bone height of  $5.19 \pm 0.56$  while after 6 months there was a significant increase in residual bone height with an average of  $13.03 \pm 1.44$  with the values ranging between 11.38 – 16.59 mm. This in turn means that the average vertical bone height gained after sinus lifting was an average of  $7.69 \pm 1.42$  with a maximum of 12.09 and a minimum of 5.56 mm. The difference was found to be statistically significant ( $p<0.001$ ). (Table 3)

The mean marginal bone loss after 6 months was found to be  $0.63 \pm 0.18$  with a minimum of 0.18 mm and a maximum of 1.04 mm. (Table 3)

**Table 1:** Comparison between the studied periods according to pain (n=12).

Pain	Number of patients (%)			Fr	p
	1 <sup>st</sup> day	2 <sup>nd</sup> day	3 <sup>rd</sup> day		
0	4 (33.3)	6 (50.0)	12 (100.0)		
1	2 (16.7)	6 (50.0)	0 (0.0)		
2	6 (50.0)	0 (0.0)	0 (0.0)	22.36*	<0.001*
Mean $\pm$ SD.	1.32 $\pm$ 0.89	0.58 $\pm$ 0.51	0.0 $\pm$ 0.0		
Range	0.0 – 2.0	0.0 – 1.0	0.0 – 0.0		
p <sub>1</sub>		0.005*	0.008*		
Pain (avg of 3 days)					
p value	<0.001				
Mean $\pm$ SD	0.63 $\pm$ 0.46				

#### Fr: Friedman test

p: p value for comparing between the studied periods

p<sub>1</sub>: p value for **Wilcoxon signed ranks test** for comparing between 1<sup>st</sup> day and each other days

\*: Statistically significant at  $p \leq 0.05$

**Table (2):** Distribution of the studied cases according to different parameters (n = 12)

Variable	No.	%
Edema		
Mild	10	83.3
Moderate	2	16.7
SMP		
No	10	83.3
Yes	2	16.7
Bleeding		
No bleeding	10	83.3
Bleeding	2	16.6
Sinusitis	0	0.0
Periimplantitis	0	0.0

**Table (3):** Comparison between the two studied periods according to ISQ, bone density, vertical bone height and marginal bone loss (n=19)

Variable	Range	Mean $\pm$ SD	p value
Implant Stability (ISQ)			
Immediate	64.0 – 97.0	69.79 $\pm$ 8.10	2.40*(0.016*)
6 months	70.0 – 79.0	75.47 $\pm$ 3.22	
Loss/Gain	-19.0 – 13.0	5.68 $\pm$ 7.97	
Bone density (HU)			1.61(0.107)
Immediate	386.9 – 1226.3	600.4 $\pm$ 226.0	
6 months	316.4 – 953.6	552.4 $\pm$ 164.9	
Loss/Gain	-240.4 – 305.0	48.05 $\pm$ 127.1	
Vertical bone height (mm)			22.277*( $<0.001^*$ )
Preoperative	4.34 – 6.0	5.19 $\pm$ 0.56	
Postoperative	11.38 – 16.59	13.03 $\pm$ 1.44	
VBH Gain	5.56 – 12.09	7.69 $\pm$ 1.42	
Marginal bone loss (mm)	0.18 – 1.04	0.63 $\pm$ 0.18	

#### Z: Wilcoxon signed ranks test

p: p value for comparing between the studied periods

\*: Statistically significant at  $p \leq 0.05$

#### t: Paired t-test

p: p value for comparing between the studied periods

\*: Statistically significant at  $p \leq 0.05$

## DISCUSSION

Rehabilitation of the posterior maxilla is a challenging task owing to the insufficient alveolar bone volume and bone resorption following extraction, maxillary sinus pneumatization and poor bone quality (2). Sinus augmentation is an established surgical procedure used to facilitate implant placement and prosthetic rehabilitation in an atrophic posterior maxilla (1).

The two basic approaches mentioned in the literature for maxillary sinus floor elevation procedure are lateral window antrotomy, which is the classic and the more commonly performed technique introduced by Tatum, and the crestal approach which is developed by Summers in 1994 (5). Recent advances in sinus augmentation include the use of surgical stents fabricated by Three Dimension (3D) printing technology as well as the use of piezoelectric surgery (17). The low window sinus lift technique is an advanced method introduced by Zaniol et al. utilizing computer guided surgery and piezoelectric technology to easily access and lift the sinus membrane while decreasing operation time and complications such as sinus membrane perforation (9).

The primary aim of this study was to evaluate the safety and effectiveness of the "Low Window" lateral sinus lifting technique.

Patients selected were free from systemic diseases that may complicate the surgical procedure and interrupt healing process of the implant. It has been reported by Hwang et al and Aghaloo et al that the risk factors for implants survival concerning systemic diseases were uncontrolled diabetes, recent myocardial infarction attacks, bleeding disorders, patients receiving IV bisphosphonate therapy, immune deficiency disorders, cardiovascular diseases, osteoporosis, chemotherapy, and postmenopausal women were associated with a significant increase in implant failure (18, 19).

Patients were selected to be free of untreated periodontal diseases and oral infection as it was concluded by Karoussis et al in 2007 and Rocuzzo et al in 2010 that patients with a history of periodontal disease display an expressively greater incidence of peri-implant marginal bone loss and peri-implantitis compared with patients with healthy periodontium (20, 21). Chon et al mentioned that the maintenance of periodontal health is essential for minimizing the risk of peri-implantitis indicating the importance of periodontal therapy and maintenance in patients with a history of periodontitis (22).

Some studies conducted mentioned that the main component of a cigarette, nicotine, is associated with a reduction in osteoblastic activity and causes microvascular obstruction which both lead to failure of bone maturation and peri-implantitis. Another component which is carbon monoxide was found to decrease the oxygen carrying capacity of the red blood cells, impairing new bone formation around implants and affecting the process of bone healing. This conclusion was in agreement with the criteria of patient selection in this study that excluded heavy smokers due to the proven detrimental effects on the peri-implant tissue (23).

Amongst the inclusion criteria of this study was that the residual bone height should be within the range 4-6mm. It was mentioned by Pal et al in 2012 that a residual ridge with height less than 6 mm is considered advanced bone resorption and, in this case, the lateral window sinus lift approach is preferred over the trans-crestal approach (8).

Various imaging techniques are available for planning implant sites prior to the operation. In the present study, a panoramic X-ray and CBCT were taken for each patient preoperatively. A CBCT was taken immediately postoperative and after 6 months for determining the

Computer-guided Low Window lateral sinus lift technique vertical bone height gained, marginal bone loss and to spot changes in the bone dentistry around implants. According to Cassetta et al in 2013 and Bornstein et al in 2014, CBCT has a wide range of uses in implant dentistry starting from preoperative evaluation, locating specific anatomic structures such as maxillary sinus and neurovascular bundles, computer aided implant planning and postoperative evaluation (24, 25).

In this study treatment planning by CBCT was performed to design the location and dimensions of the low window osteotomy. The anterior wall and floor of the maxillary sinus are determined and the window design is planned accordingly. Varied opinions amongst authors offer suggestions regarding the size of the window and the position of the inferior horizontal antrotomy line. Even though some propose placing it to be flushed with the floor of the sinus, other authors suggest to position it 2 to 3 mm higher than the floor (26).

Zaniol et al proposed the creation of a low window sinus lift technique where the position of the lateral window is as inferior and mesial as possible. In this design, the lower horizontal osteotomy is placed as low as possible to be flushed with the floor of the maxillary sinus which eliminates any need to remove excess residual bone that could hinder detachment of the Schneiderian membrane. The mesial vertical osteotomy is flushed with the anterior wall of the sinus while the distal vertical osteotomy is just behind the most distal implant. The height of the window is 6 mm to avoid the intraosseous anastomosis (9).

According to Cho et al in 2001, the angles between lateral and medial walls of the maxillary sinus contribute to the risk of Schneiderian membrane perforation. The more acute the angles are, the more frequent perforations occur. In the low window technique, the surgical access angle will always be greater than 90 degrees even if the sinus is narrow (<30 which has a high risk of perforation) (27).

Brief J et al. in 2005 concluded that improper implant positioning undermines function and esthetics, together with an increase in the risk of implant failure resulting from an overload of biomechanical forces. Surgical guides have been developed to create a relationship between prosthetic and surgical planning as well as improving the precision and safety of implant insertion. In the current study, a stereolithographic surgical stent was fabricated preoperatively based on the patient's CBCT taking into consideration vertical bone height, width, density, angulations of adjacent and opposing natural teeth and establishing an accurate maxilla-mandibular relationship for exact implant positioning as well as designing and planning the low window according to the established protocol (28).

In this study the minimum alveolar ridge height below the maxillary sinus floor before surgery was 4.37 mm and the maximum was 6 mm with an average of bone height of 5.39 mm. This is also in accordance with He et al in 2013 (29) who showed that it was possible to achieve implant stability even when the available bone height was limited down to 4-5 mm. This was also in agreement with Nedir et al in 2006 (30) who mentioned that the minimal prerequisite for achieving primary stability of an implant

was the presence of a layer of cortical bone which can be only 2 mm in length.

Concerning the postoperative clinical evaluation in this study it was found that patients had both mild pain and edema after the operation. Pain was monitored for 5 days and a Visual Analogue Scale was used to record the values. The average pain score was  $0.63 \pm 0.46$  with a minimum pain score of 1 and a maximum score of 2. All pain scores were limited to mild with a statistically significant decrease in the pain from the 1st to the 3rd day ( $p$  value  $<0.005$ ). A study conducted by Scarano et al obtained an average VAS of 3.703 on the second day for lateral sinus lifting using the traditional trapezoidal flap whereas in our study there was a significant difference with an average score of  $0.58 \pm 0.51$  on the second day (31). All patients showed signs of mild edema which is edema confined to the surgical site with the exception of 2 patients that showed moderate edema which is an extraoral swelling in the surgical zone.

Implant stability was measured immediately following insertion of implants and 6 months postoperatively prior to loading of the abutments. The average implant stability immediately following implant placement was  $69.79 \pm 8.10$  with a maximum value of 64 and a minimum of 97. Six months postoperatively, the average ISQ was  $75.47 \pm 3.22$  with a minimum value of 70 and a maximum 79. An average increase of  $5.68 \pm 7.97$  in ISQ values was observed. Similar results were obtained by Jelušić et al where the average ISQ values 4 months after sinus lifting with bone graft placement was  $78.9 \pm 6.3$ . According to the literature, ISQ numbers greater than 70 designate high implant stability and success of the implant placed (32).

A statistically significant amount ( $p < 0.001$ ) of vertical bone height gain was observed after 6 months with an average of  $7.69 \pm 1.42$  with a maximum of 12.09 mm and minimum height of 5.56 mm. Arora et al in 2019 obtained an average vertical bone height gain of  $11.23 \pm 1.25$  mm ranging from 9.5 mm to 14.8 mm (33).

Regarding the marginal bone loss (MBL) after 6 months postoperatively compared that level at the immediate postoperative period, the average MBL was found to be  $0.63 \pm 0.18$  mm with a minimum of 0.18 mm and maximum of 1.04 mm. Kunal et al in 2014 found that the marginal bone loss in 4 months following sinus augmentation was 0.68 to 1.22 mm (34). It has been mentioned by Klinge et al that MBL greater than or equal to 2 mm at the time of prosthesis delivery in addition to bleeding on probing are considered danger signs and that the case will require intervention (35). Evidence of bone formation was recorded around all implants at 6 months postoperatively. The mean bone density value was found to be  $600.4 \pm 226.0$  HU at the immediate postoperative phase and  $552.4 \pm 164.9$  HU six months postoperatively. This is was found to be a statistically insignificant change ( $p$ -value  $> 0.001$ ). In a study conducted by Arora et al, close results were obtained where the mean postoperative density gained after sinus lifting was  $525.43 \pm 104.18$  Hounsfield unit ranging from 649 HU to 350 HU (33). As mentioned by Altintas et al in 2013, the graft material must resorb before the novel bone forms. Remodeling of the graft material and the formation of new bone occurs takes a period of 9 to 12 months. This coincides with our study and justifies that there was no

Computer-guided Low Window lateral sinus lift technique statistical difference between the bone density in the two period (36).

Although this study yielded positive results in terms of pain, edema, vertical bone height gained and marginal bone loss, complications such as bleeding and sinus membrane perforation were inevitable. Perforations were immediately managed by placement of a resorbable collagen membrane. Factors contributing to the occurrence of this complication may be the presence of a fragile membrane that lacked elasticity. Mild postoperative epistaxis on the first day postoperatively is one of the most common complication as mentioned by Ragucci et al and was managed by mild nasal compression (37, 38). Longer follow up periods are needed to further evaluate the bone density and implant success.

## CONCLUSION

The low window sinus lift technique displays successful outcomes in regards of safety and effectiveness, although this is a technique sensitive treatment modality that necessitates meticulous surgical skills and planning.

### Conflict of Interest

The authors declare that they have no conflicts of interest.

## REFERENCES

1. Danesh-Sani SA, Loomer PM, Wallace SS. A comprehensive clinical review of maxillary sinus floor elevation: anatomy, techniques, biomaterials and complications. *Br J Oral Maxillofac Surg.* 2016;54:724-30.
2. Cavalcanti MC, Guirado TE, Sapata VM, Costa C, Pannuti CM, Jung RE, César Neto JB. Maxillary sinus floor pneumatization and alveolar ridge resorption after tooth loss: a cross-sectional study. *Braz Oral Res.* 2018;32:e64.
3. Tatum OHJ, Lebowitz MS, Tatum CA, Borgner RA. Sinus augmentation. Rationale, development, long-term results. *N Y State Dent J.* 1993;59:43-8.
4. Boyne PJ, James RA. Grafting of the maxillary sinus floor with autogenous marrow and bone. *J Oral Surg.* 1980;38:613-6.
5. Aghaloo T, Misch C, Lin GH, Iacono V, Wang HL. Bone Augmentation of the Edentulous Maxilla for Implant Placement: A Systematic Review. *Int J Oral Maxillofac Implants.* 2016;31:19-30.
6. Summers RB. A new concept in maxillary implant surgery: the osteotome technique. *Compendium.* 1994;15:152, 154-6, 158 passim; quiz 162.
7. Trombelli L, Franceschetti G, Rizzi A, Minenna P, Minenna L, Farina R. Minimally invasive transcrestal sinus floor elevation with graft biomaterials. A randomized clinical trial. *Clin Oral Implants Res.* 2012;23:424-32.
8. Pal US, Sharma NK, Singh RK, Mahammad S, Mehrotra D, Singh N, et al. Direct vs. indirect sinus lift procedure: A comparison. *Natl J Maxillofac Surg.* 2012;3:31-7.
9. Zaniol T, Zaniol A. A Rational Approach to Sinus Augmentation: The Low Window Sinus Lift. *Case Rep Dent.* 2017;2017:7610607.
10. Marin S, Kirnbauer B, Rugani P, Payer M, Jakse N. Potential risk factors for maxillary sinus membrane

- perforation and treatment outcome analysis. *Clin Implant Dent Relat Res.* 2019;21:66-72.
11. Liddel G, Klineberg I. Patient-related risk factors for implant therapy. A critique of pertinent literature. *Aust Dent J.* 2011;56:417-26; quiz 441.
  12. Cuschieri S. The STROBE guidelines. *Saudi J Anaesth.* 2019;13:S31-4.
  13. Osman AH, Mansour H, Atef M, Hakam M. Computer guided sinus floor elevation through lateral window approach with simultaneous implant placement. *Clin Implant Dent Relat Res.* 2018;20:137-43.
  14. Faul F, Erdfelder E, Lang AG, Buchner A. G\*Power 3: a flexible statistical power analysis program for the social, behavioral, and biomedical sciences. *Behav Res Methods.* 2007 May;39(2):175-91. doi: 10.3758/bf03193146. PMID: 17695343.
  15. Johnson C. Measuring Pain. Visual Analog Scale Versus Numeric Pain Scale: What is the Difference? *J Chiropr Med.* 2005;4:43-4.
  16. Shah SA, Khan I, Shah HS. Effectiveness of submucosal dexamethasone to control postoperative pain & swelling in apicectomy of maxillary anterior teeth. *Int J Health Sci (Qassim).* 2011;5:156-65.
  17. Colombo M, Mangano C, Mijiritsky E, Krebs M, Hauschild U, Fortin T. Clinical applications and effectiveness of guided implant surgery: a critical review based on randomized controlled trials. *BMC Oral Health.* 2017;17:150.
  18. Aghaloo T, Pi-Anfruns J, Moshaverinia A, Sim D, Grogan T, Hadaya D. The Effects of Systemic Diseases and Medications on Implant Osseointegration: A Systematic Review. *Int J Oral Maxillofac Implants.* 2019;34:s35-49.
  19. Hwang D, Wang HL. Medical contraindications to implant therapy: Part II: Relative contraindications. *Implant Dent.* 2007;16:13-23.
  20. Karoussis IK, Kotsovilis S, Fourmoussis I. A comprehensive and critical review of dental implant prognosis in periodontally compromised partially edentulous patients. *Clin Oral Implants Res.* 2007;18:669-79.
  21. Rocuzzo M, De Angelis N, Bonino L, Aglietta M. Ten-year results of a three-arm prospective cohort study on implants in periodontally compromised patients. Part 1: implant loss and radiographic bone loss. *Clin Oral Implants Res.* 2010;21:490-6.
  22. Cho-Yan Lee J, Mattheos N, Nixon KC, Ivanovski S. Residual periodontal pockets are a risk indicator for peri-implantitis in patients treated for periodontitis. *Clin Oral Implants Res.* 2012;23:325-33.
  23. Akram Z, Vohra F, Bukhari IA, Sheikh SA, Javed F. Clinical and radiographic peri-implant parameters and proinflammatory cytokine levels among cigarette smokers, smokeless tobacco users, and nontobacco users. *Clin Implant Dent Relat Res.* 2018;20:76-81.
  24. Cassetta M, Sofan AA, Altieri F, Barbato E. Evaluation of alveolar cortical bone thickness and density for orthodontic mini-implant placement. *J Clin Exp Dent.* 2013;5:e245-52.
  25. Bornstein MM, Scarfe WC, Vaughn VM, Jacobs R. Cone beam computed tomography in implant dentistry: a systematic review focusing on guidelines, Computer-guided Low Window lateral sinus lift technique indications, and radiation dose risks. *Int J Oral Maxillofac Implants.* 2014;29:55-77.
  26. Baldini N, D'Elia C, Bianco A, Goracci C, de Sanctis M, Ferrari M. Lateral approach for sinus floor elevation: Large versus small bone window - a split-mouth randomized clinical trial. *Clin Oral Implants Res.* 2017;28:974-81.
  27. Cho SC, Wallace SS, Froum SJ, Tarnow DP. Influence of anatomy on Schneiderian membrane perforations during sinus elevation surgery: three-dimensional analysis. *Pract Proced Aesthet Dent.* 2001;13:160-3.
  28. Brief J, Edinger D, Hassfeld S, Eggers G. Accuracy of image-guided implantology. *Clin Oral Implants Res.* 2005;16:495-501.
  29. He L, Chang X, Liu Y. Sinus floor elevation using osteotome technique without grafting materials: a 2-year retrospective study. *Clin Oral Implants Res.* 2013;24:63-7.
  30. Nedir R, Bischof M, Vazquez L, Szmukler-Moncler S, Bernard JP. Osteotome sinus floor elevation without grafting material: a 1-year prospective pilot study with ITI implants. *Clin Oral Implants Res.* 2006;17:679-86.
  31. Scarano A, Lorusso F, Arcangelo M, D'Arcangelo C, Celletti R, de Oliveira PS. Lateral Sinus Floor Elevation Performed with Trapezoidal and Modified Triangular Flap Designs: A Randomized Pilot Study of Post-Operative Pain Using Thermal Infrared Imaging. *Int J Environ Res Public Health.* 2018;15:1277.
  32. Jelušić D, Puhar I, Plančak D. Assessment of implant stability following sinus lift procedures with different grafting materials. *Acta Stomatol Croat.* 2014;48:25-32.
  33. Arora A, Khadtale D, Agarwal B, Yadav R, Bhutia O, Roychoudhury A. Radiographical and histological evaluation of bioactive synthetic bone graft putty in sinus floor augmentation: A pre- and post-intervention study. *Natl J Maxillofac Surg.* 2019;10:13-9.
  34. Jodia K, Sadhwani BS, Parmar BS, Anchlia S, Sadhwani SB. Sinus elevation with an alloplastic material and simultaneous implant placement: a 1-stage procedure in severely atrophic maxillae. *J Maxillofac Oral Surg.* 2014;13:271-80.
  35. Klinge B. Peri-implant marginal bone loss: an academic controversy or a clinical challenge? *Eur J Oral Implantol.* 2012;5:S13-9.
  36. Altintas NY, Senel FC, Kayıpmaz S, Taskesen F, Pampu AA. Comparative Radiologic Analyses of Newly Formed Bone After Maxillary Sinus Augmentation With and Without Bone Grafting. *J Oral Maxillofac Surg.* 2013;71:1520-30.
  37. Ragucci GM, Elnayef B, Suárez-López Del Amo F, Wang HL, Hernández-Alfaro F, Gargallo-Albiol J. Influence of exposing dental implants into the sinus cavity on survival and complications rate: a systematic review. *Int J Implant Dent.* 2019;5:6.
  38. Barbu HM, Iancu SA, Jarjour Mirea I, Mignogna MD, Samet N, Calvo-Guirado JL. Management of Schneiderian Membrane Perforations during Sinus Augmentation Procedures: A Preliminary Comparison of Two Different Approaches. *J Clin Med.* 2019;8:1491

ADDJ