



Placement of dental implants in atrophic jaw with divided crest and ridge expansion technique

Colocación de implantes dentales en maxilar atrófico con técnica de cresta dividida y expansión del reborde

Juan Reyes Doimi,* Guillermo Mauricio Aguirre Balseca,[§] Andréé Cáceres La Torre*

ABSTRACT

The present case report describes placement of tooth implants in a patient with history of smoking, exhibiting severe, chronic periodontitis and maxillary atrophy with horizontal bone volume deficiency. Simultaneously to implant placement, the technique of divided crest, ridge expansion and bovine bone graft placement was used. After six months, bone integration of all implants was observed and a hybrid, implant-supported prosthesis was manufactured (full bone anchorage). Finally the case was followed for 18 months without observing any complications, and with satisfactory functional and esthetic results for the patient.

RESUMEN

Este reporte de caso describe la colocación de implantes dentales en un paciente con antecedente del hábito de fumar y que presenta periodontitis crónica severa y atrofia maxilar con deficiencia de volumen óseo en sentido horizontal. Simultáneamente a la colocación de implantes se utilizó la técnica de cresta dividida, expansión del reborde y colocación de injerto óseo bovino. Después de seis meses, se observó la oseointegración de todos los implantes y se procedió a la confección de la prótesis implantosoportada de tipo híbrida (anclaje óseo completo). Finalmente, se realizó el seguimiento del caso durante un periodo de 18 meses sin observar complicaciones y con un resultado funcional y estético satisfactorio para el paciente.

Key words: Crest expansion technique, bone ridge expansion, ridge increase.

Palabras clave: Técnica de expansión crestal, expansión de reborde óseo, aumento de reborde.

INTRODUCTION

One of the main criteria to select a patient for candidacy to tooth implant placement is availability of bone volume.^{1,2} Literature reports that minimum bone dimension required to place an implant should be 5 mm wide (bucca-palatal/lingual) and between 7 and 10 mm high.^{3,4} Nevertheless, in practice, there is a great number of patients requiring dental implants who lack ideal bone circumstances. Among these circumstances, the most frequent is insufficient bone volume, which can be due to the following: alveolar ridge atrophy due to tooth absence, periodontal disease or as sequel of some trauma or condition. These insufficient bone situations are called alveolar ridge deformities; they have been classified according to their morphology.⁵ According to this classification, class I consists on bone loss in buccal-lingual direction, this provides more predictable results when applying techniques of horizontal bone volume increase.^{6,7} Among these techniques, the following are described: autogenous bone graft techniques,⁸ block bone allografts,⁹ and bone ridge expansion

techniques.¹⁰ Nevertheless, autogenous block bone graft, up to this date, is the technique most frequently used and is considered the gold standard due to the fact it has shown satisfactory long term results.¹¹ On the other hand, disadvantages of this technique must also be considered: there can be greater morbidity due to donor zone and waiting time required before implant placement.¹² On the contrary, this article purports to present the technique called divided crest with bone expansion and placement of organic bovine bone graft as an alternative to the rehabilitation in a case of

* Professor, Periodontics Master's Degree, San Martin de Porres University, Peru.

[§] Professor, Universidad de Los Hemisferios, Ecuador.

Received: February 2016. Accepted: October 2016.

© 2017 Universidad Nacional Autónoma de México, [Facultad de Odontología]. This is an open access article under the CC BY-NC-ND license (<http://creativecommons.org/licenses/by-nc-nd/4.0/>).

This article can be read in its full version in the following page: <http://www.medigraphic.com/facultadodontologiaunam>

maxillary atrophy, performed at the Dental Clinic of the Universidad de Los Hemisferios, Quito, Ecuador.

CASE REPORT

Patient

A 55 year old male patient in apparent good health attended the Dental Clinic of the University Los Hemisferios, Quito Ecuador requesting manufacture of a prosthesis for his upper jaw; the patient additionally informed of tooth mobility and discomfort when speaking or chewing. As relevant history, the patient informed he suffered controlled blood hypertension and habit of smoking over ten cigarettes a day.

Clinical examination

Intraoral examination revealed absence of most teeth in the upper jaw, tooth extrusion, presence of abundant dental plaque and calculi, presence of periodontal pockets larger than 7 mm, dental caries, multiple gingival recessions and evident atrophy of upper alveolar ridge affecting patient's facial aesthetics.

Radiographic examination

Radiographic examination revealed generalized horizontal bone resorption, pneumatization of both maxillary sinuses, caries in tooth 1.3, radio-lucid lesions at the height of periapex of teeth 1.3, 1.4, 2.6 and 4.4 (*Figure 1*).

Diagnosis

Based on information harvested from clinical and radiographic examinations, the following diagnoses were established: severe generalized chronic periodontitis in tooth 1.3, dental abscesses in teeth 1.3, 1.4, 2.6 and 4.4 as well as upper and lower partial edentulism with upper alveolar ridge atrophy and bilateral maxillary sinuses pneumatization.

Tomographic evaluation

A cone beam computerized tomography was indicated in order to assess remaining bone availability which could allow implant placement. Tomographic evaluation revealed that, in the upper jaw, in spite of generalized bone resorption, there was sufficient bone mass to place a crown-apical implant. Contrarily, in buccal/palatal direction, no sufficient bone mass was

found for conventional implant placement (*Figure 2*). Therefore, this jaw would correspond to Seibert's class III alveolar ridge deformities, thus, the need arose to perform additional surgical procedures to allow placement of at least six implants.

The lower jaw exhibited a bone defect compromising vestibular and lingual aspects of remaining bone at the level of tooth 4.2. Nevertheless, sufficient bone mass was found to place four implants in the inter-foramen area.

Treatment

Considering that the patient was a heavy smoker and the poor periodontal circumstances exhibited by his teeth, the following procedures were undertaken: patient was instructed to quit smoking and to continue with treatment, oral hygiene instruction was provided, roots were scaled and planed, all upper and lower teeth were extracted and provisional prostheses were manufactured. After this, placement of six implants for the upper jaw and four implants for the lower jaw was planned in order to manufacture implant supported prostheses (full bone anchorage) at a later point in treatment.

Surgical procedure

Upper Jaw

Half an hour before commencing surgical procedure, patient was medicated with amoxicillin, 1 g, orally, dexamethasone 4 mg and ketorolac 60 mg intramuscularly. Intraoral asepsis was achieved with 0.12% chlorhexidine, extraoral asepsis was conducted with iodopovidone. Surgery was performed with local anesthesia (lidocaine 2% with epinephrine 1:100,000).

A full thickness incision over the crest was performed, raising a mucoperiosteal flap exposing bone table up to 4 mm from the top of the crest in vestibular direction;

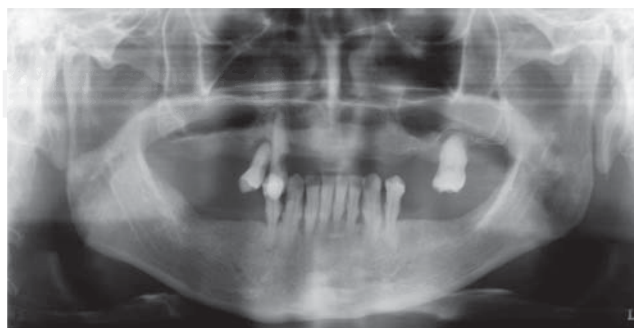


Figure 1. Generalized horizontal bone resorption and bilateral maxillary sinuses pneumatization.

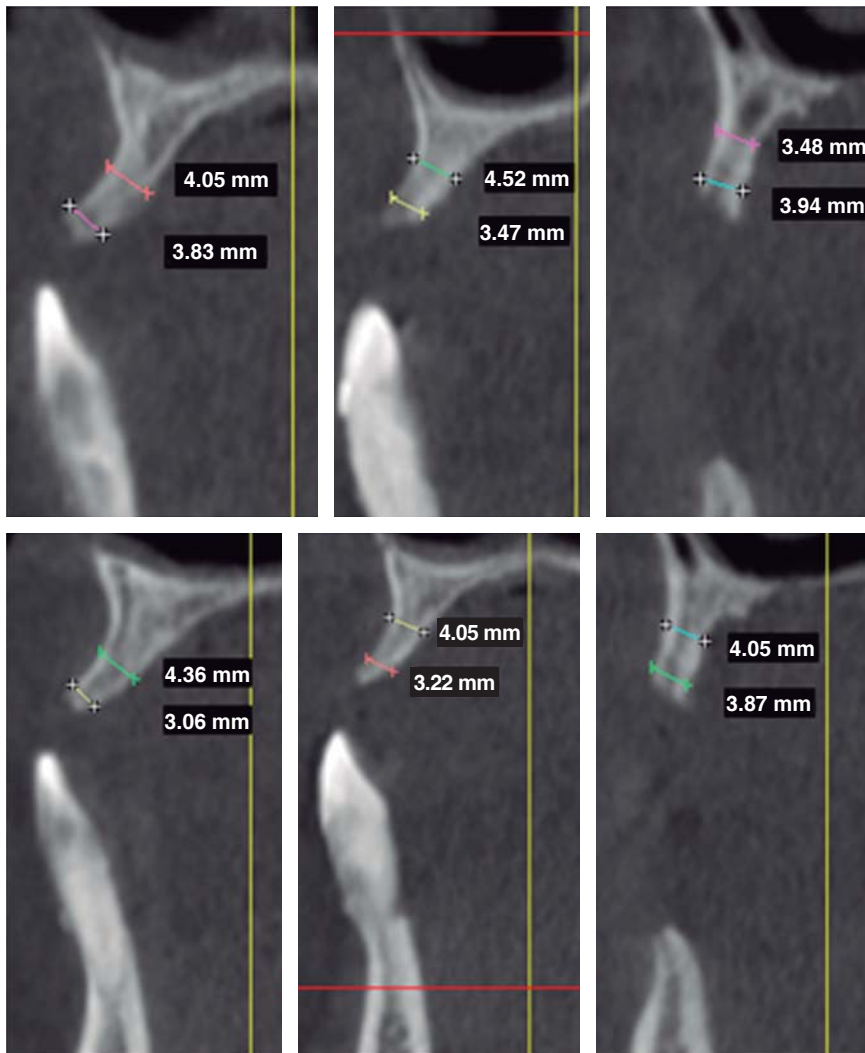


Figure 2.

CBCT showing generalized horizontal bone resorption, although sufficient bone was vertically found in apical-crown direction. From left to right, upper jaw: area of teeth 1.1, 1.2 and 1.4. From left to right in lower jaw: teeth number 2.1, 2.2 and 2.4.

from that point the flap was divided into partial thickness (*Figure 3*). After this, impact points were marked in designated places according to surgical guide for implant placement; perforations were initiated with a 1.6 mm diameter burr in order to determine desired implant depth and axis. After this, a ridge was created on the crest with a diamond burr, fracturing cortical bone to create chisel's access to cancellous bone, and with the aforementioned, bone tables were separated until reaching a 5 mm depth (*Figures 4 y 5*). Perforations were further continued with a 2.0 diameter burr (*Figure 6*), and vestibular table expansion was undertaken creating greenstick fracture with the expanders, until reaching sufficient osseous bed diameter (3.2 mm diameter) (*Figures 7 y 8*). Implants were then placed at a 25 rpm speed and 35 Nem torque (*Figures 9 y 10*). After this, a particulate bovine bone graft was placed (Bonefill® Bionnovation Biomedical, Sao Paulo, Brazil)

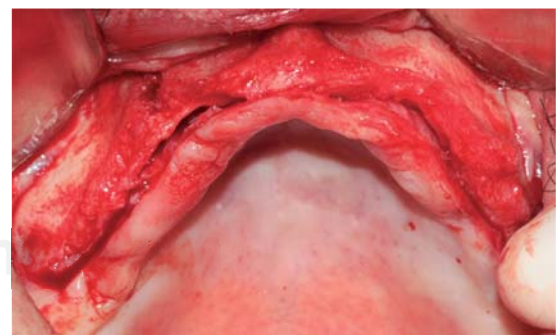


Figure 3. Occlusal view of mucoperiosteal flap elevation exposing vestibular bone.

with the aim of preserving integrity of vestibular bone tables (*Figure 11*). All these procedures were repeated for placement of all six implants. Finally, sutures were undertaken with monofilament nylon 5/0.

Lower jaw

For this surgical procedure, the patient received the same pre-surgical preparation than that used for the upper jaw. Procedure was initiated with an incision between grooves at the level of all teeth, after which a mucoperiosteal flap was raised. Teeth were then extracted and adjacent granulation tissue was removed, trying to preserve all bone remnants. After this, bone ridge was regularized and remodeled using multi-laminated burs with abundant irrigation. With a conventional burr sequence, perforations were then initiated at places designed for implant placement. After this, all four implants were placed, locating prosthetic platforms at one same level. Since there was presence of bone defects and three walls around the implants, particulate bovine bone graft was placed (Bonefill® (R) Bionnovation Biomedical, Sao Paulo, Brazil). Finally, sutures were applied with monofilament nylon 5/0.

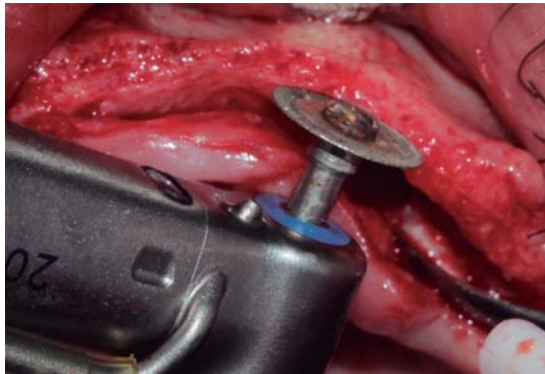


Figure 4. Diamond disc (0.5 mm thick) used to create a crest groove passing through cortical bone and allowing access for bone chisel.

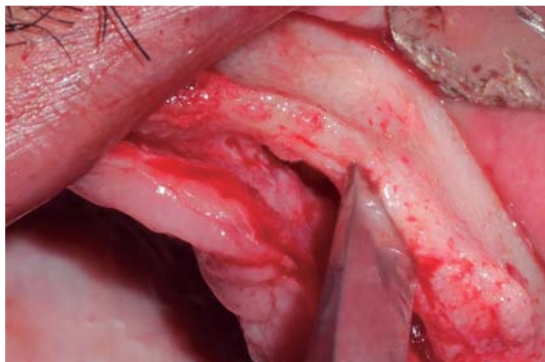


Figure 5. Bone chisel entering medullar portion, separating cortical ridge leading to greenstick fracture.

Postsurgical medication

Amoxicillin, 500 mg orally every 8 hours for five days.
Ketarolac, 60 mg intramuscularly every 12 hours for one day.

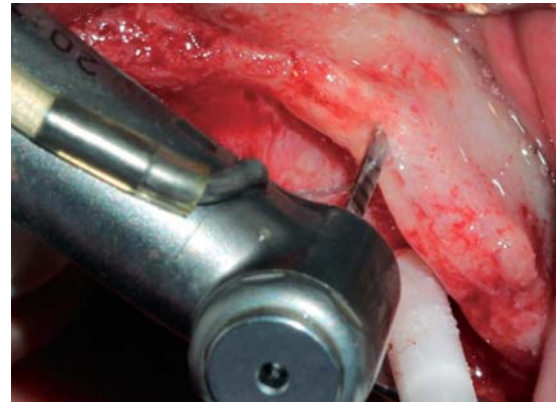


Figure 6. Bone preparation using a 2 mm diameter burr.

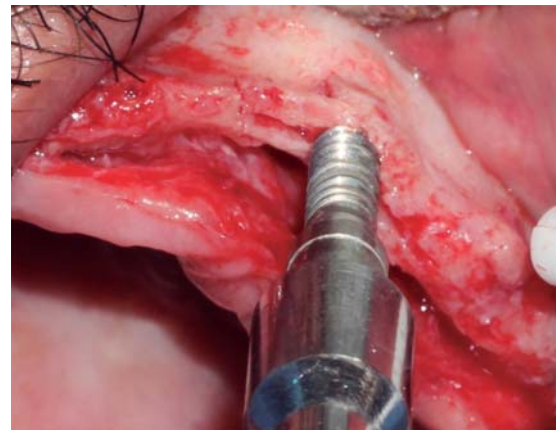


Figure 7. Bone widening using expanders, creating suitable access for a greater diameter burr.

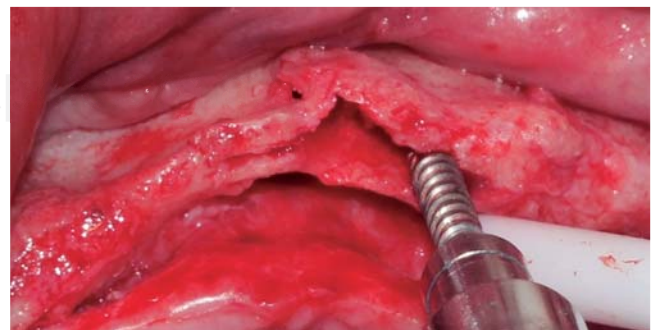


Figure 8. Bone expander placed distally with respect to the preparation, avoiding a fracture of the vestibular table.

Dexamethasone, 4 mg, intramuscularly, every 12 hours for one day.

Ketarolac, 10 mg orally every 8 days for three days.
Mouth rinses with 0.12% chlorhexidine gluconate.

This protocol was indicated for surgical procedures of both jaws.

Post-surgical controls were conducted after 24 hours, seven days and 14 days. No complications were observed and suture points were removed.

After six months, radiographic evaluation was conducted, which revealed preserved bone tissue surrounding the implants and no signs of complications. After this, surgical exposition and healing screw placement was undertaken and bone integration of all implants was observed.

Implant supported prosthesis

Two weeks later, manufacture of implant-supported prosthesis for both jaws was undertaken. Both prostheses were of hybrid design (full bone anchorage).

The case was followed for 18 months; no complications were observed and final result was functional and aesthetically satisfactory.

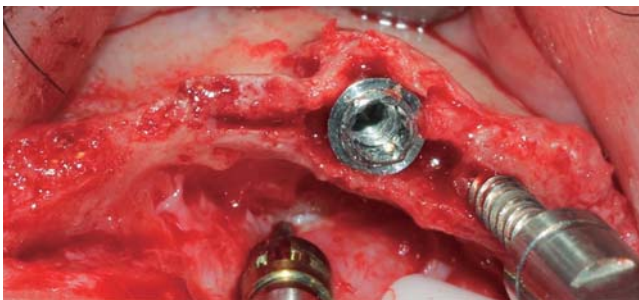


Figure 9. Implant measuring 3.75 mm diameter placed before removing distal bone expander.

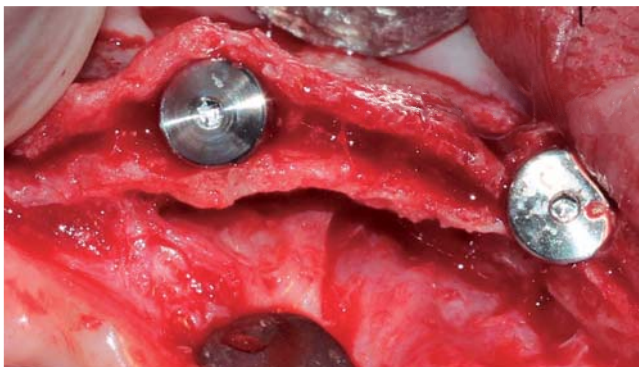


Figure 10. Implants placed with 25 rpm and 35 Ncm.

DISCUSSION

Split-crest technique allows primary stabilization of tooth implants in atrophied bone ridges by means of bone expansion. This technique can be indicated as an alternative to regenerative procedures avoiding morbidity of donor sites, decreasing the number of surgical procedures and treatment time.¹³ Nevertheless, bone defect morphology is an important consideration for the techniques' suitability. Requirements are: an alveolar ridge mostly composed of medullar bone, with a wide base and crest in the shape of a knife blade, with sufficient bone height (10 mm at least) and width of 3 to 5 mm.^{13,14} Thus, the technique purports the objective of creating a space through the division of the bone crest into two sections, with greenstick longitudinal fracture, allowing immediate insertion and stabilization of implants in the most apical, non- fractured portion of the bone ridge.¹⁴

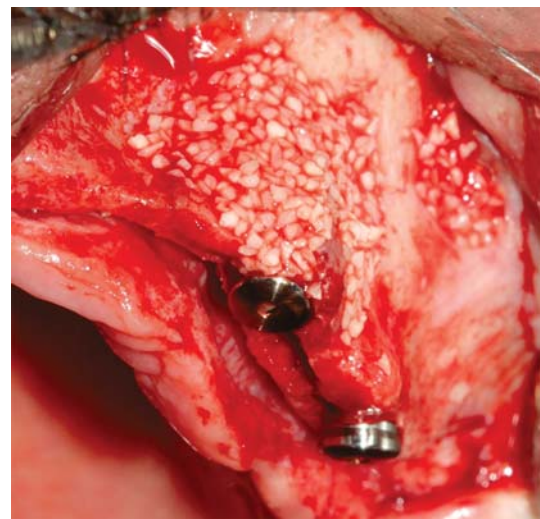


Figure 11. Bovine xenograft placed in the vestibular area of all implants.

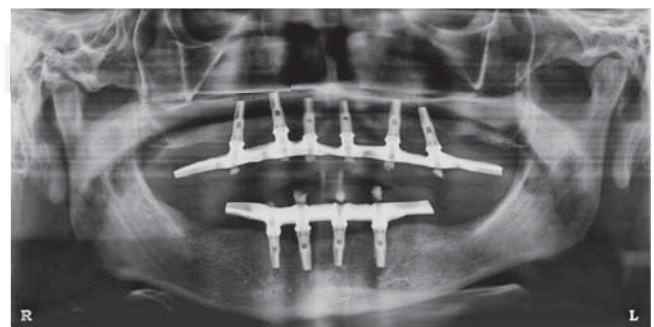


Figure 12. Implant-supported prosthesis installed in both jaws.

This intact bone region in the apical portion must be able to allow for a 3 to 4 mm deep preparation as a minimum, in order to obtain primary stability during implant insertion.^{13,14}

Another important aspect during bone preparation is the use of surgical guides as protocol to avoid unfavorable implant inclination. Some studies describe an excessive inclination of implants in the direction of the vestibular table which was moved during the expansion procedure thus functionally and aesthetically compromising final treatment result.^{10,15,16}

Moreover, it has been said that it is frequently necessary to fixate with wire the fractured table onto the palatal table; this would render the procedure more complex, and in some cases, the ligature could be prematurely exposed; this would require an additional procedure to remove it before the implants complete the period of osseointegration.¹⁷

The Split Crest technique provided horizontal ridge increase of about 1-4 mm; the upper jaw exhibited the greatest increase (4-3 mm) when compared to the lower jaw (1-1.5 mm).¹⁴ Likewise, greater numbers of complications have been reported when this technique has been used in the lower jaw.¹⁸ Therefore, indications for this procedure are more frequent and bear better prognosis when used in the upper jaw. It is worth mentioning there is controversy with respect to use of biomaterials during performance of Split Crest procedures. Use of membranes,^{14,19} bone grafts¹⁷ and materials such as tricalcium phosphate β (β -TCP) associated to platelet rich plasma¹³ have been described.

It has been reported that use of membranes as a barrier along with bone expansion entails greater difficulty for flap primary healing, increasing possibility of membrane exposition and infection during post-operative periods.²⁰ Other reports compare inter-cortical bone space obtained after expansion with an extraction site that does not require filling with graft, they highlight the importance of periosteum and matrix in the regenerative process.²¹ Nevertheless, the present article describes use of bone graft composed of bovine inorganic matrix to fill osseous beds resulting from table division. Thus, the bone graft is surrounded by bone walls and also covered by periosteum, allowing ingress of osteoblasts and pre-osteoblasts into the graft.^{17,22} Bone reparation followed by this procedure is similar to that of a fracture, non-elevated vestibular mucoperiosteum is responsible for vascular nutrition and fixation of mobilized bone segment. After a five month period, a trabeculated area was observed with mature bone characteristics and remodeling capacity as well as the ability to withstand functional

loads through the implants.²³ For this reason reports advise to wait for a six month healing period before loading the implants.^{13,14,17}

Likewise, in the case described in the present article, it was decided to wait for six months before subjecting the implants to functional loads. Moreover, all implants were bone-integrated and were loaded without any complication at an 18 month follow-up period. This result concurs with the survival and success rates of implants placed with the split crest technique reported by other authors.^{13,14,18,19}

Due to all the aforementioned facts, it is recommended to carefully select those cases where this technique can be used, taking into consideration ridge morphology and bone density. It is also suggested to carefully handle all tissues in order to preserve periosteum integrity and use filling material to reduce risk of vestibular bone table loss.

REFERENCES

1. Albrektsson T, Dahl E, Enbom L, Engvall S, Engquist B, Eriksson AR et al. Osseointegrated oral implants. A Swedish multicenter study of 8139 consecutively inserted Nobelpharma implants. *J Periodontol.* 1988; 59 (5): 287-296.
2. Adell R, Eriksson B, Lekholm U, Brånemark PI, Jemt T. Long-term follow-up study of osseointegrated implants in the treatment of totally edentulous jaws. *Int J Oral Maxillofac Implants.* 1990; 5 (4): 347-359.
3. Lekholm U, Zarb GA. *Patient selection and preparation.* In: Brånemark PI, Zarb GA, Albrektsson T, editors. *Tissue-integrated prostheses: osseointegration in clinical dentistry.* Chicago: Quintessence Publishing Co; 1985. pp. 199-209.
4. Misch CE. Divisions of available bone in implant dentistry. *Int J Oral Implantol.* 1990; 7 (1): 9-17.
5. Seibert JS. Reconstruction of deformed, partially edentulous ridges, using full thickness onlay grafts. Part I. Technique and wound healing. *Compend Conti Educ Dent.* 1983; 4 (5): 437-453.
6. Buser D, Dula K, Hirt HP, Schenk RK. Lateral ridge augmentation using autografts and barrier membranes: A clinical study with 40 partially edentulous patients. *J Oral Maxillofac Surg.* 1996; 54 (4): 420-432.
7. Misch CM. Comparison of intraoral donor sites for onlay grafting prior to implant placement. *Int J Oral Maxillofac Implants.* 1997; 12 (6): 767-776.
8. Misch CM, Misch CE, Resnik RR, Ismail YH. Reconstruction of maxillary alveolar defects with mandibular symphysis grafts for dental implants: A preliminary procedural report. *Int J Oral Maxillofac Implants.* 1992; 7 (3): 360-366.
9. Keith JD Jr. Localized ridge augmentation with block allograft followed by secondary implant placement: a case report. *Int J Periodontics Restorative Dent.* 2004; 24(1): 11-17.
10. Sethi A, Kaus T. Maxillary ridge expansion with simultaneous implant placement: 5-years results of an ongoing clinical study. *Int J Oral Maxillofac Implants.* 2000; 15 (4): 491-499.
11. Levin L, Nitzan D, Schwartz-Arad D. Success of dental implants placed in intraoral block bone grafts. *J Periodontol.* 2007; 78 (1): 18-21.
12. Williamson RA. Rehabilitation of the resorbed maxilla and mandible using autogenous bone grafts and osseointegrated implants. *Int J Oral Maxillofac Implants.* 1996; 11 (4): 476-488.

13. Basa S, Varol A, Turker N. Alternative bones expansion technique for immediate placement of Implants in the edentulous posterior mandibular ridge: a clinical report. *Int J Oral Maxillofac Implants*. 2004; 19 (4): 554-558.
14. Simion M, Baldoni M, Zaffe D. Jawbone enlargement using immediate implant placement associated with a split-crest technique and guided tissue regeneration. *Int J Periodontics Dent*. 1992; 12 (6): 463-473.
15. Wijs F, Cune MS. Immediate labial contour restoration for improved esthetics: a radiographic study on bone splitting in anterior single-tooth replacement. *Int J Oral Maxillofac Implants*. 1997; 12 (5): 686-696.
16. Ferrigno N, Laureti M. Surgical advantages with ITI TE implants placement in conjunction with split crest technique. 18-month results of an ongoing prospective study. *Clin Oral Implants Res*. 2005; 16 (2): 147-155.
17. Coatoam GW, Mariotti A. The segmental ridge-split procedure. *J Periodontol*. 2003; 74 (5): 757-770.
18. Engelke WG, Diederichs CG, Jacobs HG, Deckwer I. Alveolar reconstruction with splitting osteotomy and microfixation of implants. *Int J Oral Maxillofac Implants*. 1997; 12 (3): 310-318.
19. Shimoyama T, Kaneko T, Shimizu S, Kasai D, Tojo T, Horie N. Ridge widening and immediate implant placement: a case report. *Implant Dent*. 2001; 10 (2): 108-112.
20. Buser D, Dula K, Hirt HP, Schenk RK. Lateral ridge augmentation using autografts and barrier membranes: a clinical study with 40 partially edentulous patients. *J Oral Maxillofac Surg*. 1996; 54 (4): 420-432; discussion 432-433.
21. Scipioni A, Bruschi GB, Calesini G. The edentulous ridge expansion technique: a five-year study. *Int J Periodontics Restorative Dent*. 1994; 14 (5): 451-459.
22. Gray JC, Elves MW. Donor cells' contribution to osteogenesis in experimental cancellous bone grafts. *Clin Orthop Relat Res*. 1982; (163): 261-271.
23. Scipioni A, Bruschi GB, Calesini G, Bruschi E, De Martino C. Bone regeneration in the edentulous ridge expansion technique: histologic and ultrastructural study of 20 clinical. *Int J Periodontics Restorative Dent*. 1999; 19 (3): 269-277.

Mailing address:

Juan Reyes Doimi

E-mail: drreyesdoimi@hotmail.com